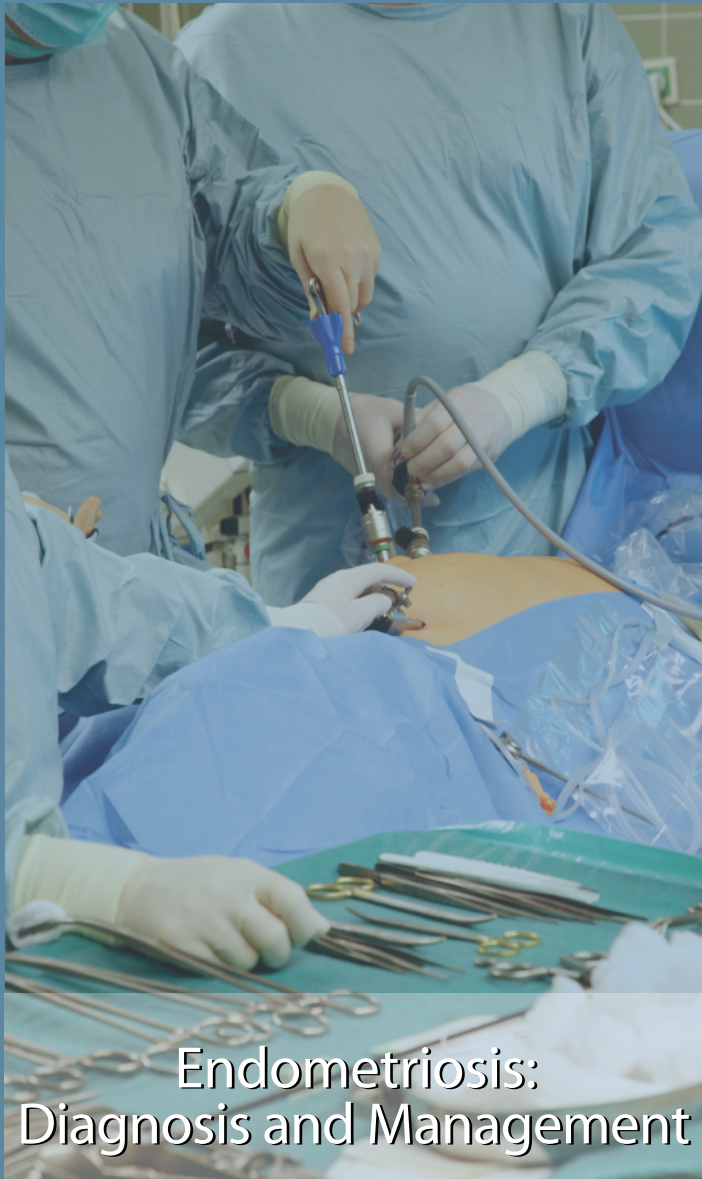



Endometriosis: Diagnosis and Management

Abstract	S1
Chapter 1: Introduction	S4
Chapter 2: Pain Management	S6
Chapter 3: Medical Management of Pain Associated With Endometriosis	S9
Chapter 4: Surgical Management of Endometriosis	S15
Chapter 5: Surgical Management of Infertility Associated With Endometriosis	S19
Chapter 6: Medical Treatment of Infertility Related to Endometriosis	S21
Chapter 7: Endometriosis in Adolescents	S23
Chapter 8: Endometriosis and Cancer	S26



Editor-in-Chief / Rédacteur en chef

Timothy Rowe

CPL Editor / Rédactrice PPP

Vyta Senikas

Translator / Traducteur

Martin Pothier

Assistant Editor / Rédactrice adjointe

Jane Fairbanks

Editorial Assistant /

Adjointe à la rédaction

Daphne Sams

Editorial Office /

Bureau de la rédaction

Journal of Obstetrics and
Gynaecology Canada
Room D 405A
Women's Health Centre Building
4500 Oak Street
Vancouver BC V6H 3N1
editor@sogc.com
Tel: (604) 875-2424 ext. 5668
Fax: (604) 875-2590

The Journal of Obstetrics and Gynaecology Canada (JOGC) is owned by the Society of Obstetricians and Gynaecologists of Canada (SOGC), published by the Canadian Psychiatric Association (CPA), and printed by Dollco Printing, Ottawa, ON.

Le Journal d'obstétrique et gynécologie du Canada (JOGC), qui relève de la Société des obstétriciens et gynécologues du Canada (SOGC), est publié par l'Association des psychiatres du Canada (APC), et imprimé par Dollco Printing, Ottawa (Ontario).

Publications Mail Agreement no. 40026233. Return undeliverable Canadian copies and change of address notices to SOGC, JOGC Subscription Service, 780 Echo Dr., Ottawa ON K1S 5R7. USPS #021-912. USPS periodical postage paid at Champlain, NY, and additional locations. Return other undeliverable copies to International Media Services, 100 Walnut St., #3, PO Box 1518, Champlain NY 12919-1518.

Numéro de convention poste-publications 40026233. Retourner toutes les copies canadiennes non livrées et les avis de changement d'adresse à la SOGC, Service de l'abonnement au JOGC, 780, promenade Echo, Ottawa (Ontario), K1S 5R7. Numéro USPS 021-912. Frais postaux USPS au tarif des périodiques payés à Champlain (NY) et autres bureaux de poste. Retourner les autres copies non livrées à International Media Services, 100 Walnut St., #3, PO Box 1518, Champlain (NY) 12919-1518.

ISSN 1701-2163

Endometriosis: Diagnosis and Management

This Clinical Practice Guideline has been reviewed by the Clinical Practice Gynaecology Committee and reviewed and approved by the Executive and Council of the Society of Obstetricians and Gynaecologists of Canada.

PRINCIPAL AUTHORS

Nicholas Leyland, MD, Toronto ON
Robert Casper, MD, Toronto ON
Philippe Laberge, MD, Quebec QC
Sukhbir S. Singh, MD, Ottawa ON

SPECIAL CONTRIBUTORS

Lisa Allen, MD, Toronto ON
Kristina Arendas, MD, Ottawa ON

CLINICAL PRACTICE GYNAECOLOGY COMMITTEE

Nicholas Leyland, MD (Chair), Toronto ON
Catherine Allaire, MD, Vancouver BC
Alaa Awadalla, MD, Winnipeg MB
Carolyn Best, MD, Hamilton ON
Elizabeth Contestabile, RN, Ottawa ON
Sheila Dunn, MD, Toronto ON
Mark Heywood, MD, Vancouver BC
Nathalie Leroux, MD, Montreal QC
Frank Potestio, MD, Thunder Bay ON
David Allan Rittenberg, MD, Halifax NS
Sukhbir S. Singh, MD, Ottawa ON
Renée Soucy, MD, Chandler QC
Wendy Lynn Wolfman, MD, Toronto ON
Vyta Senikas, MD, Ottawa, ON

Disclosure statements have been received from all members of the committee.

The literature searches and bibliographic support for this guideline were undertaken by Becky Skidmore, Medical Research Analyst, Society of Obstetricians and Gynaecologists of Canada.

Key Words: Endometriosis, endometrioma, pelvic pain, infertility, laparoscopy

Abstract

Objective: To improve the understanding of endometriosis and to provide evidence-based guidelines for the diagnosis and management of endometriosis.

Outcomes: Outcomes evaluated include the impact of the medical and surgical management of endometriosis on women's experience of morbidity and infertility.

Methods: Members of the guideline committee were selected on the basis of individual expertise to represent a range of practical and academic experience in terms of both location in Canada and type of practice, as well as subspecialty expertise along with general gynaecology background. The committee reviewed all available evidence in the English and French medical literature and available data from a survey of Canadian women. Recommendations were established as consensus statements. The final document was reviewed and approved by the Executive and Council of the SOGC.

Results: This document provides a summary of up-to-date evidence regarding diagnosis, investigations, and medical and surgical management of endometriosis. The resulting recommendations may be adapted by individual health care workers when serving women with this condition.

Conclusions: Endometriosis is a common and sometimes debilitating condition for women of reproductive age. A multidisciplinary approach involving a combination of lifestyle modifications, medications, and allied health services should be used to limit the impact of this condition on activities of daily living and fertility. In some circumstances surgery is required to confirm the diagnosis and provide therapy to achieve the desired goal of pain relief or improved fecundity. Women who find an acceptable management strategy for this condition may have an improved quality of life or attain their goal of successful pregnancy.

Evidence: Medline and Cochrane databases were searched for articles in English and French on subjects related to endometriosis, pelvic pain, and infertility from January 1999 to October 2009 in order to prepare a Canadian consensus guideline on the management of endometriosis.

Values: The quality of evidence was rated with use of the criteria described by the Canadian Task Force on Preventive Health Care. Recommendations for practice were ranked according to the method described by the Task Force. See Table 1.

Benefits, harms, and costs: Implementation of the guideline recommendations will improve the care of women with pain and infertility associated with endometriosis.

This document reflects emerging clinical and scientific advances on the date issued and is subject to change. The information should not be construed as dictating an exclusive course of treatment or procedure to be followed. Local institutions can dictate amendments to these opinions. They should be well documented if modified at the local level. None of these contents may be reproduced in any form without prior written permission of the SOGC.

Table 1. Key to evidence statements and grading of recommendations, using the ranking of the Canadian Task Force on Preventive Health Care*

Quality of evidence assessment†	Classification of recommendations‡
I: Evidence obtained from at least one properly randomized controlled trial	A. There is good evidence to recommend the clinical preventive action
II-1: Evidence from well-designed controlled trials without randomization	B. There is fair evidence to recommend the clinical preventive action
II-2: Evidence from well-designed cohort (prospective or retrospective) or case-control studies, preferably from more than one centre or research group	C. The existing evidence is conflicting and does not allow to make a recommendation for or against use of the clinical preventive action; however, other factors may influence decision-making
II-3: Evidence obtained from comparisons between times or places with or without the intervention. Dramatic results in uncontrolled experiments (such as the results of treatment with penicillin in the 1940s) could also be included in this category	D. There is fair evidence to recommend against the clinical preventive action
III: Opinions of respected authorities, based on clinical experience, descriptive studies, or reports of expert committees	E. There is good evidence to recommend against the clinical preventive action
	L. There is insufficient evidence (in quantity or quality) to make a recommendation; however, other factors may influence decision-making

*Wolf SH, Battista RN, Angerson GM, Logan AG, Eel W. Canadian Task Force on Preventive Health Care. New grades for recommendations from the Canadian Task Force on Preventive Health Care. *Can Med Assoc J* 2003;169(3):207-8.

†The quality of evidence reported in these guidelines has been adapted from the Evaluation of Evidence criteria described in the Canadian Task Force on Preventive Health Care.*

‡Recommendations included in these guidelines have been adapted from the Classification of Recommendations criteria described in the Canadian Task Force on Preventive Health Care.*

Summary Statements and Recommendations

Chapter 1: Introduction

Summary Statements

1. Endometriosis is common, affecting 5% to 10% of the female population, and the significance of the disease depends on the clinical presentation. (II-3)
2. The cellular and molecular etiologic theories of endometriosis as an inflammatory and estrogen-dependent disorder have improved our understanding. (III)

Chapter 2: Pain Management

Summary Statements

1. Symptoms may vary; however, certain hallmark symptoms may be more likely to suggest endometriosis. The clinician should be aware of atypical presentations. (I)
2. Endometriosis can be a chronic, relapsing disorder, which may necessitate a long-term follow-up. (I)
3. When deeply infiltrating endometriosis is suspected, a pelvic examination, including rectovaginal examination, is essential. (III)

Recommendations

1. Investigation of suspected endometriosis should include history, physical, and imaging assessments. (III-A)
2. Routine CA-125 testing as part of the diagnostic investigation of endometriosis should not be performed. (II-2D)

Chapter 3: Medical Management of Pain Associated With Endometriosis

Recommendations

1. Combined hormonal contraceptives, ideally administered continuously, should be considered as first-line agents. (I-A)

2. Administration of progestin alone—orally, intramuscularly, or subcutaneously—may also be considered as first-line therapy. (I-A)
3. A GnRH agonist with HT addback, or the LNG-IUS, should be considered a second-line therapeutic option. (I-A)
4. A GnRH agonist should be combined with HT addback therapy from commencement of therapy and may be considered for longer-term use (> 6 months). (I-A)
5. While awaiting resolution of symptoms from the directed medical or surgical treatments for endometriosis, practitioners should use clinical judgement in prescribing analgesics ranging from NSAIDs to opioids. (III-A)

Chapter 4: Surgical Management of Endometriosis

Summary Statements

1. Treatment of endometriosis by excision or ablation reduces pain. (I)
2. For women with endometriomas, excision rather than drainage or fulguration provides better pain relief, a reduced recurrence rate, and a histopathological diagnosis. (I)
3. Laparoscopic uterine nerve ablation alone does not offer significant relief of endometriosis-related pain. (I)

Recommendations

1. An asymptomatic patient with an incidental finding of endometriosis at the time of surgery does not require any medical or surgical intervention. (III-A)
2. Surgical management in women with endometriosis-related pain should be reserved for those in whom medical treatment has failed. (III-A)
3. Surgical treatment of deeply infiltrating endometriosis may require particular experience with a multidisciplinary approach. (III-A)

- Ovarian endometriomas greater than 3 cm in diameter in women with pelvic pain should be excised if possible. (I-A)
- In patients not seeking pregnancy, therapy with CHCs (cyclic or continuous) should be considered after surgical management of ovarian endometriomas. (I-A)
- Presacral neurectomy may be considered as an adjunct to the surgical treatment of endometriosis-related pelvic pain. (I-A)

Chapter 5: Surgical Management of Infertility Associated With Endometriosis

Summary Statements

- Laparoscopic treatment of minimal or mild endometriosis improves pregnancy rates regardless of the treatment modality. (I)
- The effect on fertility of surgical treatment of deeply infiltrating endometriosis is controversial. (II)
- Laparoscopic excision of ovarian endometriomas more than 3 cm in diameter may improve fertility. (II)

Chapter 6: Medical Treatment of Infertility Related to Endometriosis

Summary Statement

- If a patient with known endometriosis is to undergo IVF, GnRH agonist suppression with HT addback for 3 to 6 months before IVF is associated with an improved pregnancy rate. (I)

Recommendation

- Medical management of infertility related to endometriosis in the form of hormonal suppression is ineffective and should not be offered. (I-E)

Chapter 7: Endometriosis in Adolescents

Summary Statements

- Endometriosis is the most common cause of secondary dysmenorrhea in adolescents. (II-2)
- Adolescents with endometriosis are more likely than adult women to present with acyclic pain. (III)
- The physical examination of adolescents with endometriosis will rarely reveal abnormalities, as most will have early-stage disease. (II-2)

Recommendations

- Endometriosis in adolescents is often early stage and atypical. Laparoscopists should look intra-abdominally for clear vesicles and red lesions in adolescents. (II-2B)
- All available therapies for endometriosis may be used in adolescents, but the age of the patient and the side-effect profiles of the medications should be considered. (III-A)

Chapter 8: Endometriosis and Cancer

Summary Statements

- The prevalence of ovarian cancer in patients with endometriosis is under 1%. (II-2)
- Excision or sampling of suspected endometriosis lesions and endometriomas helps confirm the diagnosis and exclude underlying malignancy. (II-2)

Recommendations

- Biopsy of endometriosis lesions should be considered to confirm the diagnosis and to rule out underlying malignancy. (II-2A)
- Suspected ovarian endometriomas should be treated according to the SOGC guideline "Initial Evaluation and Referral Guidelines for Management of Pelvic/Ovarian Masses." (III-A)

ABBREVIATIONS

ASRM	American Society of Reproductive Medicine
BMD	bone mineral density
CHCs	combined hormonal contraceptives
DMPA	depot medroxyprogesterone acetate
GnRH	gonadotropin releasing hormone
HT	hormone therapy
IVF	in vitro fertilization
LNG-IUS	levonorgestrel intrauterine system
MRI	magnetic resonance imaging
NSAIDs	nonsteroidal anti-inflammatory drugs
RCT	randomized controlled trial

Introduction

Endometriosis, one of the most common disease entities confronting gynaecologists, is defined as the presence of endometrial glands and stroma tissue outside the uterus. The presence of this ectopic tissue evokes an estrogen-dependent chronic inflammatory process. This disease affects 5% to 10% of women of reproductive age.¹ Patients may present with pain, subfertility, or a combination of these problems; the disease may be suspected from pelvic examination or imaging studies. The primary focus of investigation and treatment should be directed at resolution of the presenting symptom(s). However, because endometriosis is a chronic, relapsing disorder, clinicians should develop a long-term plan of management with each patient that is dependent on her symptoms and goals for fertility and quality of life.

At present there is no consensus on the cellular or molecular origins of this disease.² Despite advances in the understanding of endometriosis, clinicians are still faced with a paucity of rigorous science behind the management of this enigmatic disorder. This guideline serves to update the SOGC Canadian consensus conferences on endometriosis of 1993 and 1999 and attempts to draw upon all literature and international guidelines to facilitate the care of Canadian women with endometriosis.

INCIDENCE AND PREVALENCE

For endometriosis, the overall incidence (annual occurrence) and prevalence (proportion of the population with the disease) are believed to be 5% to 10% of women of reproductive age.¹ The studies whose reports were used to derive these figures were compromised by selection bias, the limitations of surgical diagnosis of the disease, and the detection bias associated with retrospective studies.

Clinicians need to be aware of a number of factors that increase the likelihood of endometriosis in an individual patient. Heritability studies indicate that the probability of endometriosis is 3 to 10 times greater among first-degree relatives of women with this disease than among control subjects.³ Women with anomalous reproductive tracts and resultant obstruction of menstrual outflow are also at increased risk of endometriosis. Increased parity and

prolonged or irregular menses decrease the likelihood of the disease, whereas nulliparity, subfertility, and prolonged intervals since pregnancy are all associated with an increased risk of endometriosis.³

The highest incidence of endometriosis is in women who undergo laparoscopic assessment of infertility or pelvic pain: endometriosis will be diagnosed in 20% to 50%. The recognition of endometriotic lesions as having a much wider range of appearance than previously identified has been associated with increased identification rates.⁴

ETIOLOGY

The details of the complex etiologic theories of endometriosis are beyond the scope of this guideline; readers are referred to a recent review of this topic.⁵

At present there is no consensus on the cellular origin of endometriosis. Failure of immune mechanisms to destroy the ectopic tissue and abnormal differentiation of endometriotic tissue have been suggested as underlying mechanisms in a stromal-cell defect associated with increased estrogen and prostaglandin production, along with resistance to progesterone.²

Sampson⁶ is credited with the theory of retrograde menstruation, whereby menstrual tissue refluxes through the fallopian tubes and implants on pelvic structures. This mechanism has been consistently observed in humans and is supported by the anatomic distribution of implants of endometriotic tissue. This theory does not explain the observation that reflux menstruation occurs in most women but the disease in only 5% to 10% of the female population.

In the coelomic-metaplasia theory, endometriotic lesions develop when coelomic mesothelial cells of the peritoneum undergo metaplasia. Another theory postulates the circulation and implantation of ectopic menstrual tissue via the venous or the lymphatic system, or both.

Although none of these theories can completely explain the origin and behaviour of this enigmatic disease, our present understanding of the molecular mechanisms of endometriosis forms the basis for much of our therapeutic

approach. Endometriosis cell survival and growth and associated inflammation are responsible for the clinical symptoms of infertility and pain. Inflammation, a predominant feature of endometriotic lesions, is characterized by overproduction of cytokines, prostaglandins, and other inflammatory substances that mediate pain and may be associated with subfertility. Estrogen promotes the survival and persistence of endometrial lesions, as may altered immune and inflammatory processes.

The cellular and molecular etiologic theories have significantly improved medical and surgical approaches to the resolution of endometriosis symptoms, but continued

research, both basic and clinical, is needed to better understand and manage this disorder.

Summary Statements

1. Endometriosis is common, affecting 5% to 10% of the female population, and the significance of the disease depends on the clinical presentation. (II-3)
2. The cellular and molecular etiologic theories of endometriosis as an inflammatory and estrogen-dependent disorder have improved our understanding. (III)

REFERENCES

1. Waller KG, Lindsay P, Curtis P, Shaw RW. The prevalence of endometriosis in women with infertile partners. *Eur J Obstet Gynecol Reprod Biol* 1993;48:135–9.
2. Bulun SE. Endometriosis. *N Engl J Med* 2009;360:268–79.
3. Wheeler JM. Epidemiology and prevalence of endometriosis. *Infertil Reprod Med Clin North Am* 1992;3:545–9.
4. Rawson JM. Prevalence of endometriosis in asymptomatic women. *J Reprod Med* 1991;36:513–5.
5. Giudice LC, Kao LC. Endometriosis. *Lancet* 2004;364:1789–99.
6. Sampson JA. Peritoneal endometriosis due to menstrual dissemination of endometrial tissue into the peritoneal cavity. *Am J Obstet Gynecol* 1927;14:422–69.

Clinical Tips

- Clinicians need to be aware of the clinical factors that increase the likelihood of endometriosis.
- The primary focus of investigation and treatment of endometriosis should be resolution of the presenting symptoms.

Pain Management

The diagnosis of endometriosis-related pain requires careful evaluation through history-taking, physical examination, and appropriate investigations. Endometriosis should be considered early in the differential diagnosis of pelvic pain in young women to help avoid the reported delay, often from 7 to 12 years, from onset of symptoms to definitive diagnosis.¹⁻³

HISTORY

The signs and symptoms of endometriosis vary greatly and may be related to other conditions or pathological processes. A full evaluation and assessment of a patient's pain experience is required to assist with diagnosis and treatment.^{4,5}

Pain related to endometriosis may present as any of the following.

- Painful menstruation (dysmenorrhea)
- Painful intercourse (dyspareunia)
- Painful micturition (dysuria)
- Painful defecation (dyschezia)
- Lower back or abdominal discomfort
- Chronic pelvic pain (non-cyclic abdominal and pelvic pain of at least 6 months' duration).⁶

Atypical presentations suggesting more significant disease involvement include cyclic leg pain or sciatica (nerve involvement), cyclic rectal bleeding or hematuria (bowel or bladder invasion), and cyclic dyspnea secondary to catamenial pneumothorax.

Although endometriosis may present through the above symptoms and signs, many women with endometriosis are asymptomatic; the lesions may be an incidental finding at surgery. Also, the symptoms may not appear immediately after menarche but may develop later in life. Those with pain from endometriosis often live with a condition that is considered a chronic, progressive, and relapsing process.

For all patients with these chief complaints a detailed pain and gynaecologic history should be taken to explore and rule out other causes of pain (Table 2.1). Focused history-taking would also include reproductive health questions

(on age at menarche, cycle frequency and regularity, previous pregnancies, and use of oral contraception or hormonal treatments). Contributory medical and surgical history, as well as family history of endometriosis or gynaecologic cancers, should be sought. Tools for evaluating pelvic pain are available through the International Pelvic Pain Society (<http://www.pelvicpain.org>).

Summary Statements

1. Symptoms may vary; however, certain hallmark symptoms may be more likely to suggest endometriosis. The clinician should be aware of atypical presentations. (I)
2. Endometriosis can be a chronic, relapsing disorder, which may necessitate a long-term follow-up. (I)

Clinical Tips

- Pelvic pain that is not primary dysmenorrhea should be considered endometriosis until proven otherwise.
- Endometriosis should be considered early in the differential diagnosis of pelvic pain in young women since there is often a delay of 7 to 12 years from the onset of symptoms to definitive diagnosis.

EXAMINATION

Physical examination is essential to determine the diagnosis and appropriate care, as well as to rule out other disorders, including acute conditions that may require immediate attention. Examination should include an assessment to determine the position, size, and mobility of the uterus: a fixed, retroverted uterus may suggest severe adhesive disease. A rectovaginal examination may be necessary and appropriate to palpate the uterosacral ligaments and rectovaginal septum, which may reveal tender nodules suggestive of deeply infiltrating endometriosis. Adnexal masses discovered on physical examination may suggest ovarian endometriomas. Examination during menses may improve the chances of detecting deeply infiltrating nodules and the assessment of pain.⁷

Table 2.1. Differential diagnosis for pelvic pain

Uterine
Primary dysmenorrhea
Adenomyosis
Bowel
Irritable bowel syndrome
Inflammatory bowel disease
Chronic constipation
Bladder
Interstitial cystitis
Urinary tract infection
Urinary tract calculi
Ovarian
Mittelschmerz (ovulation pain)
Ovarian cysts (rupture, torsion, etc.)
Ovarian remnant syndrome
Fallopian tube
Hematosalpinx (after sterilization or endometrial ablation)
Ectopic pregnancy (acute or chronic)
Pelvic inflammatory disease
General
Endometriosis
Myofascial pain
Neuropathic pain
Pelvic congestion
Adhesions

INVESTIGATIONS

Ultrasonography is the first-line investigational tool for suspected endometriosis. It allows detection of ovarian cysts and other pelvic disorders such as uterine fibroids. There is little support for the routine use of blood work or other imaging studies in the primary investigation of these cases. Although the serum level of cancer antigen 125 (CA-125) may be elevated in moderate to severe endometriosis, its determination is not recommended as part of routine investigation. In a meta-analysis of 23 studies investigating serum CA-125 levels in women with surgically confirmed endometriosis, the estimated sensitivity was only 28% for a specificity of 90%.⁸ However, any undiagnosed pelvic mass should be evaluated according to the SOGC guidelines,⁹ in which the CA-125 level is a component of the Risk of Malignancy Index.

Recommendations

1. Investigation of suspected endometriosis should include history, physical, and imaging assessments. (III-A)
2. Routine CA-125 testing as part of the diagnostic investigation of endometriosis should not be performed. (II-2D)

When endometriosis is thought to have a deeply invasive component (i.e., bowel or bladder invasion), ancillary tests such as colonoscopy, cystoscopy, rectal ultrasonography, and MRI may be required.

The gold standard for diagnosis is direct visualization at laparoscopy and histologic study. Disease severity is best described by the appearance and location of the endometriotic lesions and any organ involvement. The American Society for Reproductive Medicine has developed a classification to allow staging of endometriosis at laparoscopy.¹⁰ This type of classification has limited utility for clinical management since disease stage may not correlate with the patient's symptoms. Most communications to health care providers will include a classification of disease as minimal, mild, moderate, or severe, which is described in the ASRM classification system. It is important to appreciate that the diagnosis and description of disease are highly subjective and will vary among practitioners. Video and image capturing systems allow for objective documentation of disease at laparoscopy.

Diagnostic laparoscopy is not required before treatment in all patients presenting with pelvic pain. Although laparoscopy is considered a minimally invasive procedure, it still carries the risks of surgery, including bowel and bladder perforation and vascular injury. The overall risk of any complication with laparoscopy, minor or major, is 8.9%.¹¹

Summary Statement

3. When deeply infiltrating endometriosis is suspected, a pelvic examination, including rectovaginal examination, is essential. (III)

REFERENCES

1. Arruda MS, Petta CA, Abrao MS, Benetti-Pinto CL. Time elapsed from onset of symptoms to diagnosis of endometriosis in a cohort study of Brazilian women. *Hum Reprod* 2003;18:756–9.
2. Hadfield R, Mardon H, Barlow D, Kennedy S. Delay in the diagnosis of endometriosis: a survey of women from the USA and UK. *Hum Reprod* 1996;11:878–80.
3. Husby GK, Haugen RS, Moen MH. Diagnostic delay in women with pain and endometriosis. *Acta Obstet Gynecol Scand* 2003;82:649–53.
4. Fauconnier A, Chapron C. Endometriosis and pelvic pain: epidemiological evidence of the relationship and implications. *Hum Reprod Update* 2005;11:595–606.

5. Jarrell JF, Vilos GA, Allaire C, Burgess S, Fortin C, Gerwin R; Chronic Pelvic Pain Committee. Consensus guidelines for the management of chronic pelvic pain, part 1. SOGC Clinical Practice Guideline No. 164, August 2005. *J Obstet Gynaecol Can* 2005;27:781–826.
6. Milburn A, Reiter RC, Rhomberg AT. Multidisciplinary approach to chronic pelvic pain. *Obstet Gynecol Clin North Am* 1993;20:643–61.
7. Koninckx PR, Meuleman C, Oosterlynck D, Cornillie FJ. Diagnosis of deep endometriosis by clinical examination during menstruation and plasma CA-125 concentration. *Fertil Steril* 1996;65:280–7.
8. Mol BW, Bayram N, Lijmer JG, Wiegerinck MA, Bongers MY, van der Veen F, et al. The performance of CA-125 measurement in the detection of endometriosis: a meta-analysis. *Fertil Steril* 1998;70:1101–8.
9. Le T, Giede C, Salem S. Initial evaluation and referral guidelines for management of pelvic/ovarian masses. *J Obstet Gynaecol Can* 2009;31:668–73.
10. American Society for Reproductive Medicine (ASRM). Revised American Society for Reproductive Medicine classification of endometriosis: 1996. *Fertil Steril* 1997;67:817–21.
11. Chapron C, Fauconnier A, Goffinet F, Breart G, Dubuisson JB. Laparoscopic surgery is not inherently dangerous for patients presenting with benign gynecologic pathology: results of a meta-analysis. *Hum Reprod* 2002;17:1334–42.

Medical Management of Pain Associated With Endometriosis

Endometriosis is a chronic and often progressive inflammatory condition of the pelvis whose predominant symptom is pain. The overall amount of endometriosis is not related to the frequency or severity of symptoms, and the condition's etiology remains unknown. Thus, by necessity, medical therapy is non-specific and aimed at alleviating symptoms. Since there is no cure, medical treatments must be effective and safe to use until the age of menopause or until pregnancy is desired. See Figure.

IS PRIOR LAPAROSCOPY REQUIRED?

Laparoscopy is not always necessary before medical management of pelvic pain is started. In women with severe dysmenorrhea or chronic pelvic pain that is compromising their quality of life, management of the pain is required whether or not endometriosis is the cause. Since all the management strategies for endometriosis are relatively general strategies to decrease inflammatory conditions in the pelvis, the treatments are applicable to pelvic pain whether a diagnosis of endometriosis is made or not.

The presence of endometriosis can be strongly suspected in cases of severe dysmenorrhea unresponsive to NSAID treatment, with pelvic tenderness and nodularity on palpation of the uterosacral ligaments and rectovaginal septum, or with ultrasound documentation of an ovarian cyst with an appearance typical of an endometrioma. In these situations, laparoscopy for diagnosis is not necessary before medical treatment. Laparoscopy should generally be performed only if the surgeon is prepared to vaporize or excise lesions if endometriosis is discovered, since there is good evidence that surgical management provides long-term pain relief for up to 50% of patients with endometriosis.¹⁻³

COMBINED ESTROGEN AND PROGESTIN THERAPY

The use of oral contraceptives that combine estrogen and progestin is considered first-line treatment for pelvic pain associated with endometriosis. Surprisingly, although oral contraceptives have been used for years, only a few RCTs

comparing their use with other methods of medical management have been conducted.

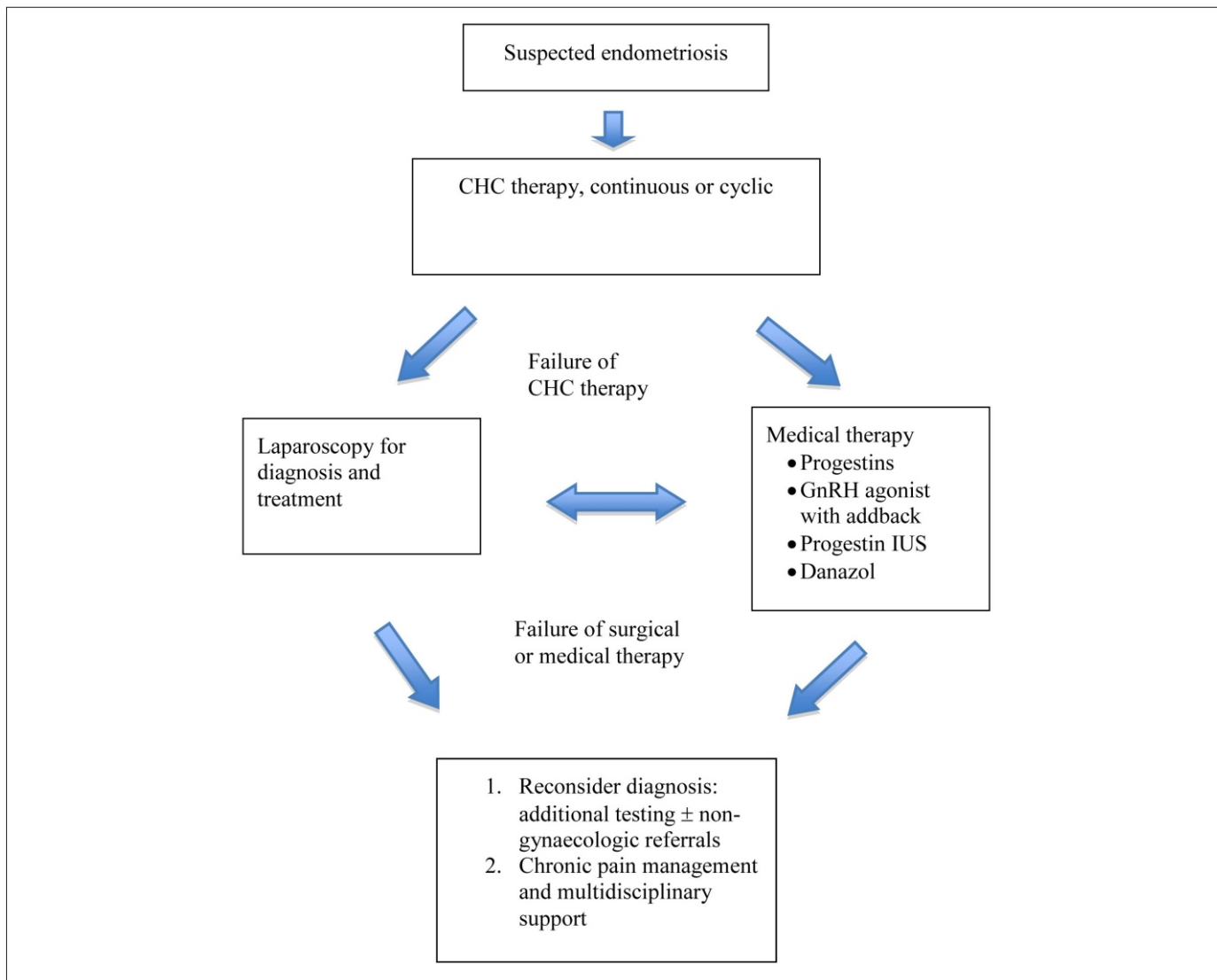
Recently, Harada et al.⁴ randomly assigned 100 women with chronic pelvic pain secondary to endometriosis to therapy with a low-dose oral contraceptive or placebo cyclically for 4 cycles. There was significant relief of dysmenorrhea with the oral contraceptives compared with placebo but no difference in relief of non-menstrual pelvic pain.

In a prospective non-controlled trial 71 women with laparoscopically documented endometriosis and chronic pelvic pain were treated with CHCs for 3 months. Although 30 patients had some reduction in, or complete relief of, pain after 3 months of treatment, 41 had no improvement.⁵

Both of these studies used cyclic administration of oral contraceptives. There are some data to suggest that continuous administration, without a 7-day break, to avoid withdrawal bleeding, may be more beneficial in terms of pain relief.^{6,7} Biologically this is plausible since it is believed that patients with endometriosis are prone to retrograde menstruation. Cyclic menstrual bleeding associated with the withdrawal of birth control pills each month may be associated with some retrograde spill of blood containing cytokines and other inflammatory chemicals secreted by the ischemic and sloughing endometrium. Therefore, preventing withdrawal bleeding may improve the efficacy of oral contraceptives for relief of pain associated with endometriosis.

One of the reasons that CHCs may not be universally effective in managing pain in patients with endometriosis relates to the status of the estrogen and progestin receptors in the ectopic endometrial implants. It is generally agreed that the estrogen receptors are normal but that the progesterone receptor isoforms PRA and PRB are markedly diminished in number or absent. As a result, endometriotic lesions may not recognize progestins, and the enzyme that metabolizes estradiol to estrone, 17- β -hydroxysteroid dehydrogenase, may not be activated appropriately by progestin action. As a result, the endometriotic implants may recognize the pharmacologic dose of estrogen in oral

Management of Pain Associated With Suspected Endometriosis



contraceptives that is needed to inhibit ovulation without receiving the estrogen-antagonistic effects of the progestin. These receptor changes are summarized nicely in reviews by Bulun et al.^{8,9}

ORAL PROGESTIN THERAPY

Estrogen stimulates endometriotic growth. Since oral contraceptives contain both estrogen and progestin, progestins alone have been used for the management of chronic pain in patients with endometriosis.

Norethindrone Acetate

Norethindrone acetate, 5 to 20 mg daily, has been effective in most patients for relieving dysmenorrhea and chronic pelvic pain.¹⁰ This treatment results in breakthrough

bleeding in about half the patients but seems to have a positive effect on calcium metabolism, resulting in relatively good maintenance of BMD. There may be negative effects on serum levels of high-density lipoprotein cholesterol. Continuous use to treat endometriosis is approved by the US Food and Drug Administration, but this agent is not available in Canada.

Dienogest

Dienogest is a progestin with selective 19-nortestosterone and progesterone activity.¹¹ It is available in Europe and may soon be approved for use in Canada. In a daily dose of 2 mg it has been significantly better than placebo in relieving pelvic pain and dysmenorrhea related to endometriosis and as effective as daily GnRH agonist therapy in relieving pain

associated with endometriosis.^{12,13} Earlier studies showed the efficacy of dienogest to be comparable with that of the depot GnRH agonist triptorelin.¹⁴ Data from a randomized study presented at the European Society of Human Reproduction and Embryology annual meeting in 2009 showed that dienogest, 2 mg daily, was as effective as the GnRH agonist leuprolide acetate, 3.75 mg intramuscularly every 4 weeks, over the 24 weeks of the study, in relieving dysmenorrhea, dyspareunia, and pelvic pain in 186 women with documented endometriosis and pelvic pain.¹⁵ Quality of life was slightly improved in the women receiving dienogest compared with those receiving leuprolide acetate, although no addback was used in the latter, and most of the side effects were related to low levels of estrogen. Overall, these studies demonstrated that dienogest is not inferior to GnRH agonists and may be an effective long-term treatment option for endometriosis.

DEPOT PROGESTIN THERAPY

DMPA, injected intramuscularly, is widely used worldwide for birth control and has been studied for the relief of endometriosis pain. A subcutaneous formulation of DMPA (104 mg), not currently available in Canada, has been investigated in 2 RCTs that compared it with leuprolide acetate depot.^{16,17} Over the 6-month study period, and for up to 12 months thereafter, DMPA-SC was equivalent to leuprolide acetate in relieving pain. There was some loss of BMD but not as much as in the group receiving leuprolide acetate without addback.

DMPA-SC appears to be effective in relieving pelvic pain in up to three quarters of patients and is a very economical alternative in the treatment of symptomatic endometriosis. However, prolonged delay in resumption of ovulation is a possibility, and therefore DMPA should not be suggested for women wanting a pregnancy in the near future. In addition, breakthrough bleeding may be prolonged, heavy, and difficult to correct since the progestin effect cannot be reversed quickly. Perhaps an ideal indication for DMPA is residual endometriosis after hysterectomy with or without bilateral salpingo-oophorectomy when future conception and irregular uterine bleeding are not issues. Long-term use of DMPA may be detrimental to BMD.

INTERUTERINE PROGESTIN-RELEASING SYSTEM

Levonorgestrel, a potent 19-nortestosterone-derived progestin, has been shown to have potent anti-estrogenic effects on the endometrium. An available LNG-releasing

IUS provides 20 g/d of levonorgestrel locally in the pelvis, which results in atrophic endometrium and amenorrhea in up to 60% of patients without inhibiting ovulation.¹⁸ In recent studies of the LNG-IUS, slightly more than half of patients with chronic pelvic pain and mild to moderate endometriosis were satisfied or very satisfied with the treatment after 6 months.^{19,20}

Advantages of the LNG-IUS include that it provides continuous therapy for 5 years without the need for replacement, but any problems with the system can be solved by removal. In addition, there are high local concentrations of progestin in the pelvis and less progestin secreted into the systemic circulation, so that the risk of systemic side effects is reduced.¹⁸

Disadvantages of the LNG-IUS include an expulsion rate of about 5% and a risk of pelvic infection of about 1.5%. Since ovulation is not inhibited, it is possible that the risk of ovarian endometriomas is increased. Endometrioma formation is thought to be related to ovulation and invagination of both ovarian surface epithelium and surface ectopic endometrium into inclusion cysts.²¹ The long-term effect of an LNG-IUS on BMD is not known.

The LNG-IUS may be an effective therapy for rectovaginal endometriosis, lessening dysmenorrhea and non-menstrual pelvic pain as well as significantly reducing deep dyspareunia and dyschezia²²; ultrasonography demonstrated a slight reduction in the size of fibronodular rectovaginal plaques.

DANAZOL

Danazol was the predominant medical treatment for endometriosis 2 decades ago. It is an oral "impeded" or weak androgen that is able to suppress gonadotropin secretion and induce amenorrhea.²³ Although effective in many cases of pelvic pain related to endometriosis, danazol is associated with androgenic side effects such as weight gain, acne, hirsutism, breast atrophy, and, rarely, virilization.²⁴ As a result, many patients were not able to tolerate the drug for long-term treatment. In addition, danazol has an unfavourable impact on circulating lipid concentrations,²⁵ and a small study raised the concern of an increased risk of ovarian cancer in endometriosis patients treated with danazol.²⁶ Because of these concerns, low-dose regimens or vaginal administration of danazol have been described.²⁷

GnRH AGONISTS

For women who do not respond to CHCs or progestins or have recurrence of symptoms after initial improvement,

Table 3.1. GnRH agonists available in Canada

Generic name	Brand name	Form	Dosage
Buserelin	Suprecur	Nasal spray	Buserelin comes in a nasal spray pump. The recommended dosage is 2 sprays into each nostril every 8 hours (3 times a day).
	Suprefact injectable	Daily injection	Daily injections of buserelin start with a dosage of 200 µg and increase up to a maximum of 500 µg. The final dose is the minimum needed to alleviate pain.
Goserelin	Zoladex	Monthly or 3-monthly injection	Goserelin is embedded in a small biodegradable implant about the size of a grain of rice. The implant is injected under the skin in the lower half of the abdomen once a month.
Leuprolide acetate	Lupron Depot	Monthly or 3-monthly injection	Leuprolide acetate is injected monthly or every 3 months intramuscularly into the arm or sometimes into the buttock or thigh muscles.
Naferelin	Synarel	Nasal spray	Naferelin comes in a nasal spray pump. The recommended dosage is 1 spray of the pump into 1 nostril in the morning and 1 spray into the other nostril in the evening every day. In a few women the recommended dosage does not stop menstruation. If symptoms persist in these women, the dosage may be increased to 1 spray in both nostrils morning and night.
Triptorelin pamoate	Trelstar	Monthly or 3-monthly injection	Triptorelin Pamoate is injected monthly or every 3 months as a single intramuscular injection
Triptorelin	Decapeptyl SR	Monthly and 3-monthly injection	Triptorelin is injected monthly or every 3 months as a single intramuscular injection
	Gonapeptyl	Monthly injection	

GnRH agonist treatment with HT addback should be considered as second-line treatment. A GnRH agonist should never be used without HT addback. Any standard HT regimen containing 1 mg of 17 β -estradiol or the equivalent should be adequate.

Since endometriosis is an estrogen-dependent disease, it is not surprising that GnRH-agonist therapy with induced hypoestrogenism would be effective for inactivating the pelvic lesions and resolving the pain. However, use of a GnRH agonist alone results in many symptoms of estrogen deficiency, such as hot flashes, insomnia, vaginal dryness, loss of libido, and loss of BMD, which is not always reversible.¹⁷ For this reason, GnRH agonists should not be used for any length of time in the absence of HT addback. The use of estrogen and progestin for addback is based on the hypothesis, first proposed by Barbieri²⁸ in 1992, that there is a threshold serum estrogen concentration that is low enough that endometriosis is not stimulated but high enough that hypoestrogenic symptoms are prevented. In

general, this concentration is essentially the same as that achieved with physiologic HT for menopausal women.^{29,30} Earlier studies of depot GnRH agonists avoided estrogen,³¹ used low-dose estradiol for addback,³² or used high doses of progestins alone. None of these studies demonstrated complete maintenance of BMD. Two more recent studies of low-dose estrogen with progestin addback have provided preliminary evidence for maintenance of BMD and absence of hypoestrogenic symptoms, together with lessening of endometriosis pain, for up to 5 and 10 years, respectively.^{30,33} The estrogen and progestin regimen used in these studies is also associated with amenorrhea in most women, with only a few cases of mild breakthrough bleeding.^{29,34} See Table 3.1 for GnRH agonists available in Canada.

Recommendations

1. Combined hormonal contraceptives, ideally administered continuously, should be considered as first-line agents. (I-A)

2. Administration of progestin alone—orally, intramuscularly, or subcutaneously—may also be considered as first-line therapy. (I-A)
3. A GnRH agonist with HT addback, or the LNG-IUS, should be considered a second-line therapeutic option. (I-A)
4. A GnRH agonist should be combined with HT addback therapy from the commencement of therapy and may be considered for longer-term use (> 6 months). (I-A)

AROMATASE INHIBITORS

The use of aromatase inhibitors for medical management of endometriosis is still experimental and is based on the observation that endometriotic lesions express the enzyme aromatase and are able to make their own estrogen, even in the absence of gonadotropin stimulation.³⁵ Two pilot studies examined pain relief after 6 months of daily treatment with an aromatase inhibitor together with high-dose norethindrone acetate³⁶ or an oral contraceptive.³⁷ Both showed significant (but not complete) resolution of pelvic pain in women with endometriosis who had not responded to first-line treatment. Since the women were premenopausal, the progestin or CHC was added to the aromatase inhibitor to prevent ovarian stimulation and cyst formation resulting from increased gonadotropin secretion once estrogen negative feedback was removed.³⁸ BMD was stable over the 6 months of the study. Further research is required to determine if aromatase inhibitors will be safe and effective for long-term use in women with endometriosis pain before these agents can be considered an option.

ANALGESIA

Management of pain associated with endometriosis with targeted medical therapies may require at least 1 cycle to initiate pain relief. For example, GnRH agonist therapy started in the luteal phase or during menses will not prevent dysmenorrhea and may even accentuate pain because of the initial flare effect in the first cycle. In this situation, it is appropriate to provide analgesia in the form of NSAIDs or even opioids to make the patient more comfortable until the primary medical management becomes effective.

Recommendation

5. While awaiting resolution of symptoms from the directed medical or surgical treatments for endometriosis, practitioners should use clinical judgement in prescribing analgesics ranging from NSAIDs to opioids. (III-A)

Clinical Tips

- In endometriosis treatment, all options should be administered for a minimum of 3 months, with evaluation of efficacy at the end of the trial.
- Long-term therapy with a GnRH agonist and addback with estrogen and progestin is an effective treatment option for relieving the symptoms of endometriosis. It is prudent to follow the BMD.
- CHCs are not appropriate for addback therapy.

REFERENCES

1. Sutton CJ, Ewan SP, Whitelaw N, Haines P. Prospective, randomized, double-blind, controlled trial of laser laparoscopy in the treatment of pelvic pain associated with minimal, mild, and moderate endometriosis. *Fertil Steril* 1994;62:696–700.
2. Jones KD, Haines P, Sutton CJ. Long-term follow-up of a controlled trial of laser laparoscopy for pelvic pain. *JLS* 2001;5:111–5.
3. Abbott JA, Hawe J, Clayton RD, Garry R. The effects and effectiveness of laparoscopic excision of endometriosis: a prospective study with 2–5 year follow-up. *Hum Reprod* 2003;18:1922–7.
4. Harada T, Momoeda M, Taketani Y, Hiroshi H, Terakawa N. Low-dose oral contraceptive pill for dysmenorrhea associated with endometriosis: a placebo-controlled, double-blind, randomized trial. *Fertil Steril* 2008;90:1583–8.
5. Jenkins TR, Liu CY, White J. Does response to hormonal therapy predict presence or absence of endometriosis? *J Minim Invasive Gynecol* 2008;15:82–6.
6. Vercellini P, Frontino G, De Giorgi O, Pietropaolo G, Pasin R, Crosignani PG. Continuous use of an oral contraceptive for endometriosis-associated recurrent dysmenorrhea that does not respond to a cyclic pill regimen. *Fertil Steril* 2003;80:560–3.
7. Coffee AL, Sulai PJ, Kuehl TJ. Long-term assessment of symptomatology and satisfaction of an extended oral contraceptive regimen. *Contraception* 2007;75:444–9.
8. Bulun SE, Cheng YH, Yin P, Imir G, Utsunomiya H, Attar E, et al. Progesterone resistance in endometriosis: link to failure to metabolize estradiol. *Mol Cell Endocrinol* 2006;248:94–103.
9. Bulun SE. Endometriosis. *N Engl J Med* 2009;360:268–79.
10. Muneccirci-Delate O, Karacan M. Effect of norethindrone acetate in the treatment of symptomatic endometriosis. *Int J Fertil Womens Med* 1998;43:24–7.
11. Sasagawa S, Shimizu Y, Kami H, Takeuchi T, Mita S, Imada K, et al. Dienogest is a selective progesterone receptor agonist in transactivation analysis with potent oral endometrial activity due to its efficient pharmacokinetic profile. *Steroids* 2008;73:222–31.
12. Strowitzki T, Marr J, Gerlinger C, Faustmann T, Seitz C. Dienogest is as effective as leuprolide acetate in treating the painful symptoms of endometriosis: a 24-week, randomized, multicentre, open-label trial. *Hum Reprod* 2010;25:633–41.
13. Harada T, Momoeda M, Taketani Y, Aso T, Fukunaga M, Hagino H, et al. Dienogest is as effective as intranasal buserelin acetate for the relief of pain symptoms associated with endometriosis—a randomized, double-blind, multicenter, controlled trial. *Fertil Steril* 2009;92:75–81.

14. Cosson M, Querleu D, Donnez J, Madelenat P, Konickx P, Audebert A, et al. Dienogest is as effective as triptorelin in the treatment of endometriosis after laparoscopic surgery: results of a prospective, multicenter, randomized study. *Fertil Steril* 2002;77:684–92.
15. Strowitzki T, Seitz C, Marr J, Gerlinger C, Faustmann T. Efficacy of dienogest for the treatment of endometriosis: a 24-week, randomised, open-label trial versus leuprolide acetate. Abstract presented at: 25th Annual Meeting of the European Society of Human Reproduction and Embryology; June 28–July 1, 2009; Amsterdam.
16. Schlaff WD, Carson SA, Luciano A, Ross D, Bergqvist A. Subcutaneous injection of depot medroxyprogesterone acetate compared with leuprolide acetate in the treatment of endometriosis-associated pain. *Fertil Steril* 2006;85:314–25.
17. Crosignani PG, Luciano A, Ray A, Bergqvist A. Subcutaneous depot medroxyprogesterone acetate versus leuprolide acetate in the treatment of endometriosis-associated pain. *Hum Reprod* 2006;21:248–56.
18. Behamondes L, Petta CA, Fernandes A, Monteiro I. Use of levonogestrel-releasing intrauterine system in women with endometriosis, chronic pelvic pain and dysmenorrhea. *Contraception* 2007;75(6 Suppl):S134–9.
19. Petta CA, Ferriani RA, Abrao MS, Hassan D, Rosa E Silva JC, et al. Randomized clinical trial of a levonorgestrel-releasing intrauterine system and a depot GnRH analogue for the treatment of chronic pelvic pain in women with endometriosis. *Hum Reprod* 2005;20:1993–8. Epub 2005 Mar 24.
20. Vercellini P, Aimi G, Panazza S, De Giorgi O, Pesole A, Crosignani PG. A levonorgestrel-releasing intrauterine system for the treatment of dysmenorrhea associated with endometriosis: a pilot study. *Fertil Steril* 1999;72:505–8.
21. Jain S, Dalton ME. Chocolate cysts from ovarian follicles. *Fertil Steril* 1999;72:852–6.
22. Fedele L, Bianchi S, Zanconato G, Portuese A, Raffaelli R. Use of a levonorgestrel-releasing intrauterine device in the treatment of rectovaginal endometriosis. *Fertil Steril* 2001;75:485–8.
23. Dmowski WP, Scholer HF, Mahesh VB, Greenblatt RB. Danazol—a synthetic steroid derivative with interesting physiologic properties. *Fertil Steril* 1971;22:9–18.
24. Selak V, Farquhar C, Prentice A, Singla A. Danazol for pelvic pain associated with endometriosis. *Cochrane Database Syst Rev* 2007;(4):CD000068.
25. Packard CJ, Shepherd J. Action of danazol on plasma lipids and lipoprotein metabolism. *Acta Obstet Gynecol Scand Suppl* 1994;159:35–40.
26. Cottreau CM, Ness RB, Modugno F, Allen GO, Goodman MT. Endometriosis and its treatment with danazol or lupron in relation to ovarian cancer. *Clin Cancer Res* 2003;9:5142–4.
27. Razzi S, Luisi S, Calonaci F, Altomare A, Bocchi C, Patraglia F. Efficacy of vaginal danazol treatment in women with recurrent deeply infiltrating endometriosis. *Fertil Steril* 2007;88:789–94.
28. Barbieri RL. Hormone treatment of endometriosis: the estrogen threshold hypothesis. *Am J Obstet Gynecol* 1992;166:740–5.
29. Surrey ES, Hornstein MD. Prolonged GnRH agonist and add-back therapy for symptomatic endometriosis: long-term follow-up. *Obstet Gynecol* 2002;99(5 Pt 1):709–19.
30. Mitwally MF, Gotlieb L, Casper RF. Prevention of bone loss and hypoestrogenic symptoms by estrogen and interrupted progestogen add-back in long-term GnRH-agonist down-regulated patients with endometriosis and premenstrual syndrome. *Menopause* 2002;9:236–41.
31. Hornstein MD, Surrey ES, Weisberg GW, Casino LA. Leuprolide acetate depot and hormonal add-back in endometriosis: a 12-month study. *Lupron Add-Back Study Group. Obstet Gynecol* 1998;91:16–24.
32. Zupi E, Marconi D, Sbracia M, Zullo F, De Vivo B, Exacustos C, et al. Add-back therapy in the treatment of endometriosis-associated pain. *Fertil Steril* 2004;82:1303–8.
33. Bedaiwy MA, Casper RF. Treatment with leuprolide acetate and hormonal add-back for up to 10 years in stage IV endometriosis patients with chronic pelvic pain. *Fertil Steril* 2006;86:220–2.
34. Casper RF. Estrogen with interrupted progestin HRT: a review of experimental and clinical studies. *Maturitas* 2000;34:97–108.
35. Bulun SE, Zeitoun KM, Takayama K, Sasano H. Estrogen biosynthesis in endometriosis: molecular basis and clinical relevance. *J Mol Endocrinol* 2000;25(1):35–42.
36. Ailawadi RK, Jobanputra S, Kataria M, Gurates B, Bulun SE. Treatment of endometriosis and chronic pelvic pain with letrozole and norethindrone acetate: a pilot study. *Fertil Steril* 2004;81:290–6.
37. Amsterdam LL, Gentry W, Jobanputra S, Wolf M, Rubin SD, Bulun SE. Anastrozole and oral contraceptives: a novel treatment for endometriosis. *Fertil Steril* 2005;84:300–4.
38. Higgins MJ, Davidson NE. What is the current status of ovarian suppression/ablation in women with premenopausal early-stage breast cancer? *Curr Oncol Rep* 2009;11:45–50.

Surgical Management of Endometriosis

Endometriosis should only be treated when either pain or infertility is a presenting symptom. As an incidental finding at the time of surgery, endometriosis does not require any medical or surgical treatment. Suspected ovarian endometriomas or pelvic masses should be evaluated according to the SOGC guidelines for pelvic masses.¹

The surgical management of endometriosis involves careful consideration of the indications for surgery, preoperative evaluation, surgical techniques, surgeon experience, and ancillary techniques and procedures.

INDICATIONS

Surgical management of endometriosis is indicated in the following groups.

1. Patients with pelvic pain
 - a. who do not respond to, decline, or have contraindications to medical therapy
 - b. who have an acute adnexal event (adnexal torsion or ovarian cyst rupture)
 - c. who have severe invasive disease involving the bowel, bladder, ureters, or pelvic nerves
2. Patients who have or are suspected to have an ovarian endometrioma
 - a. Patients for whom the uncertainty of the diagnosis affects management (as with chronic pelvic pain)
 - b. Patients with infertility and associated factors (i.e. pain or a pelvic mass)

Recommendations

1. An asymptomatic patient with an incidental finding of endometriosis at the time of surgery does not require any medical or surgical intervention. (III-A)
2. Surgical management in women with endometriosis-related pain should be reserved for those in whom medical treatment has failed. (III-A)

PREOPERATIVE EVALUATION

A complete preoperative evaluation will assist in planning the surgical approach, intraoperative timing, and the need for additional procedures and consultations.

Clinical Tip

The decision to move to surgery in women with pain and suspected endometriosis should be based on clinical evaluation, imaging, and effectiveness of medical treatment. The role of diagnostic laparoscopy should be limited.

The value of a serum CA-125 test in preoperative detection of endometriosis is limited. Therefore, the test is not recommended routinely before surgery but may be performed as part of the evaluation of an undiagnosed adnexal mass.

Pelvic ultrasonography, particularly transvaginal, is recommended when an adnexal mass is suspected from physical examination. Transrectal sonography, colonoscopy, barium enema radiography, and MRI may also be useful to detect deeply infiltrating endometriosis of the bowel and rectovaginal septum in patients with dyschezia and in those with deep dyspareunia with nodularity on examination. Cystoscopy should be performed if there are cyclic bladder symptoms such as hematuria.

Risks associated with surgery should be thoroughly discussed with the patient, and informed consent should be obtained and documented.

SURGICAL APPROACH

Surgery may be either “conservative” or “definitive.” Conservative surgical management of endometriosis has the goal of restoring normal anatomy and relieving pain. This approach is most often applied to women of reproductive age who wish to conceive in the future or to avoid induction of

Clinical Tip

Imaging should be based on the clinical presentation and findings on physical examination.

menopause at an early age. It may involve direct ablation, lysis, or excision of lesions, interruption of nerve pathways, removal of ovarian endometriomas, and excision of lesions invading adjacent organs (bowel, bladder, appendix, or ureter).

Definitive surgery involves bilateral oophorectomy to induce menopause and may include removal of the uterus and fallopian tubes and, ideally, excision of all visible endometriotic nodules and lesions. It should be considered in women who have significant pain and symptoms despite conservative treatment, do not desire future pregnancies and have severe disease, or are undergoing hysterectomy because of other pelvic conditions, such as fibroids or menorrhagia.

Laparoscopy is the preferred route for surgical management of endometriosis, irrespective of severity, owing to the greater visualization through a magnified view and the quicker patient recovery and return to normal activity when compared with laparotomy.² Patients with invasive endometriosis, including bowel and bladder involvement, should be referred to those with experience or advanced training in managing these cases through a multidisciplinary approach.³

SURGICAL OUTCOMES

Only a few RCTs have evaluated the surgical treatment of endometriosis. Benefit does appear to exist for laparoscopic management of endometriosis. In 1994 Sutton et al.⁴ described the first prospective RCT on this topic, in 63 women, and showed a benefit in more of those treated with laser laparoscopic ablation and uterosacral nerve ablation than those treated with expectant management: 63% versus 23%. A follow-up study showed that more than half of the women undergoing ablation were satisfied with the treatment after a mean of 73 months.⁵ In 2004, Abbott et al.⁶ demonstrated, in a group of 39 women, benefit 6 months after surgery in more of those treated with laparoscopic excision of endometriotic lesions than those undergoing diagnostic laparoscopy: 80% versus 32%. The difference in study outcome may be attributed to more advanced disease in the latter trial or to the use of excision versus laser ablation, or a combination of factors. Despite the benefits illustrated, it is important to note that a substantial proportion of women (20% to 40%) may not show improvement after surgery.

There is insufficient evidence as to whether superficial endometriotic lesions should be excised or ablated in the treatment of pain. No difference in outcome was illustrated through a small RCT by Wright et al.⁷ in 2005. This study

Table 4.1. Examples of deeply infiltrating endometriosis

Rectovaginal nodule
Bowel invasion and constriction
Bladder invasion
Ureteric invasion or compression
Nerve involvement (e.g., sciatic nerve)

included only cases of mild endometriosis and excluded those of deeply infiltrating disease and more severe disease.

Shakiba et al.⁸ in 2008 described one of the longest follow-up studies of the surgical management of endometriosis. This retrospective study calculated the risk of reoperation at 2, 5, and 7 years after the initial operations, which included laparoscopic conservative surgery (preserving the ovaries), hysterectomy with ovarian preservation, hysterectomy with removal of 1 ovary, and hysterectomy with removal of both ovaries. By 2 years, no further surgery had been required for 80% of the women who underwent local excision of endometriotic lesions versus 96% of those who had undergone hysterectomy with ovaries preserved. Thus, hysterectomy may benefit patients with pelvic pain due to endometriosis even with ovarian preservation.

Summary Statement

1. Treatment of endometriosis by excision or ablation reduces pain. (I)

DEEPLY INFILTRATING ENDOMETRIOSIS

In contrast to superficial peritoneal endometriosis, deeply infiltrating endometriosis refers to lesions that penetrate 5 mm or more. See Table 4.1 for examples. The lesions are often multifocal and deeper than is appreciated by visualization alone. A depth greater than 10 mm is related to pain.⁹ Excision of these lesions is likely to be of greater benefit in terms of pain relief than excision of superficial disease, but the evidence is limited to reports on case series in expert hands.^{10,11}

Surgery in cases of rectovaginal infiltration, with involvement of the pelvic lateral sidewall or bowel, requires a multidisciplinary approach. Preoperative consultation with another gynaecologist experienced in minimally invasive surgery as well as a general surgeon or urologist is recommended. Bowel resection may be required for pain relief^{12,13} and should be performed by those with expertise and experience in this approach. Often this may be done by a laparoscopy-assisted approach, for quicker patient recovery.

When deeply infiltrating endometriosis is diagnosed only at the time of diagnostic laparoscopy, it is preferable to avoid immediate excision. One should first obtain informed consent and conduct a proper preoperative evaluation owing to the complex nature of the disease.

Recommendation

3. Surgical treatment of deeply infiltrating endometriosis may require particular experience with a multidisciplinary approach. (III-A)

OVARIAN ENDOMETRIOMAS

Ovarian endometriomas indicate severe disease and present a surgical management challenge.¹⁴ It is important to consider the patient's desire for fertility in order to determine the level of intervention required to preserve the ovaries and their function. Surgical options include excision of the cyst wall or drainage and coagulation of the cyst bed.

Clinical Tips

- With ovarian endometriomas it is important to consider the patient's desire for fertility in order to determine the level of intervention required to preserve the ovaries and their function.
- Ovarian endometriomas are often a marker of more extensive endometriosis.

A recent Cochrane review,¹⁵ although based on only 2 RCTs^{16,17} and a total of 164 women, suggests that laparoscopic excision provides more benefits than simple laparoscopic ablation of ovarian endometriomas for pelvic pain. Excision resulted in reduced rates of endometrioma recurrence, dysmenorrhea, dyspareunia, non-menstrual pelvic pain, and requirement for further surgery. The cumulative pregnancy rate was higher in the women who underwent cystectomy.

Although there are benefits to laparoscopic excision of ovarian endometriomas, this technique has been associated with inadvertent removal of normal ovarian tissue.¹⁸ Great care must be exercised to preserve ovarian tissue during the excision. After the risks of inadvertent removal of normal ovarian tissue and the benefits of cyst excision are weighed, the decision to treat endometriomas surgically must be based on clinical presentation and surgeon preferences. It is reasonable to suggest excision of larger endometriomas

(> 3 cm in diameter) in the presence of pelvic pain but simple drainage and ablation or expectant management of smaller cysts.

Ovarian endometriomas recur in up to 30% of patients after laparoscopic excision.¹⁹ Postoperative hormonal suppression has been shown to result in a lower recurrence rate and better management of symptoms.^{20,21} In patients not seeking pregnancy, CHC therapy (cyclic or continuous) should be considered after surgery. Since the risk of malignant disease is low and there is no evidence of improved fertility as an outcome, the decision about repeat surgery should be based on symptoms and size of the cyst: the greater the pain or the size, the more likely the need for a repeat procedure.

Summary Statement

2. For women with endometriomas, excision rather than drainage or fulguration provides better pain relief, a reduced recurrence rate, and a histopathological diagnosis. (I)

Recommendations

4. Ovarian endometriomas greater than 3 cm in diameter in women with pelvic pain should be excised if possible. (I-A)
5. In patients not seeking pregnancy, therapy with CHCs (cyclic or continuous) should be considered after surgical management of ovarian endometriomas. (I-A)

ADDITIONAL SURGICAL INTERVENTIONS

Several surgical procedures have been used in addition to ablation or excision of endometriotic lesions to further improve pain relief. Laparoscopic uterosacral nerve ablation has not been shown to be effective for chronic pain relief in a large randomized control trial.²² However, upstream interruption of the presacral nerves (presacral neurectomy) has demonstrated some midline pain relief in women with endometriosis.^{23–25} Laparoscopic presacral neurectomy is both feasible and preferred over laparotomy when conducted by experienced endoscopic surgeons.

Appendectomy has been advocated in patients with chronic pelvic pain. The appendix may be affected by endometriosis, chronic inflammation, or other disorders in patients with endometriosis.^{26,27} At the time of laparoscopy, the appendix should be identified, if possible, and its appearance noted. Laparoscopic appendectomy should be considered if the appendix is obviously abnormal; however, patient consent, surgical consultations, and perioperative risk need to be considered.

Uterine suspension has been advocated to correct the retroverted uterus in women with dyspareunia. There is no report of an independent trial whose results confirm the effectiveness or clinical utility of this procedure.

Summary Statement

3. Laparoscopic uterine nerve ablation alone does not offer significant relief of endometriosis-related pain. (I)

Recommendations

6. Presacral neurectomy may be considered as an adjunct to the surgical treatment of endometriosis-related pelvic pain. (I-A)

REFERENCES

1. Le T, Giede C, Salem S.; SOGC/GOC/SCC Policy and Practice Guidelines Committee. Initial evaluation and referral guidelines for management of pelvic/ovarian masses. Joint SOGC/GOC/SCC clinical practice guideline No. 230, July 2009. *J Obstet Gynaecol Can* 2009;31:668–73.
2. Crosignani PG, Vercellini P, Biffignandi F, Costantini W, Cortesi I, Imperato E, et al. Laparoscopy versus laparotomy in conservative surgical treatment for severe endometriosis. *Fertil Steril* 1996;66:706–11.
3. Singh SS, Marcoux V, Cheung V, Martin D, Ternamian AM. Core competencies for gynecologic endoscopy in residency training: a national consensus project. *J Minim Invasive Gynecol* 2009;16(1):1–7.
4. Sutton CJ, Ewen SP, Whitelaw N, Haines P. Prospective, randomized, double-blind, controlled trial of laser laparoscopy in the treatment of pelvic pain associated with minimal, mild, and moderate endometriosis. *Fertil Steril* 1994;62:696–700.
5. Jones KD, Haines P, Sutton CJ. Long term follow up of a controlled trial of laser laparoscopy for pelvic pain. *JSLS* 2001;5:111–5.
6. Abbott J, Hawe J, Hunter D, Holmes M, Finn P, Garry R. Laparoscopic excision of endometriosis: a randomized, placebo-controlled trial. *Fertil Steril* 2004;82:878–84.
7. Wright J, Lotfallah H, Jones K, Lovell D. A randomized trial of excision versus ablation for mild endometriosis. *Fertil Steril* 2005;83:1830–6.
8. Shakiba K, Bena JF, McGill KM, Minger J, Falcone T. Surgical treatment of endometriosis: a 7-year follow-up on the requirement for further surgery. *Obstet Gynecol* 2008;111:1285–92. Erratum in: *Obstet Gynecol* 2008;112:710.
9. Cornillie FJ, Oosterlynck D, Lauweryns JM, Konickx PR. Deeply infiltrating pelvic endometriosis: histology and clinical significance. *Fertil Steril* 1990;53:978–83.
10. Chopin N, Vieira M, Borghese B, Foulot H, Dousset B, Coste J, et al. Operative management of deeply infiltrating endometriosis: results on pelvic pain symptoms according to a surgical classification. *J Minim Invasive Gynecol* 2005;12:106–12.
11. Chapron C, Dubuisson JB. Laparoscopic treatment of deep endometriosis located on the uterosacral ligaments. *Hum Reprod* 1996;11:868–73.
12. Darai E, Bazot M, Rouzier R, Houry S, Dubernard G. Outcome of laparoscopic colorectal resection for endometriosis. *Curr Opin Obstet Gynecol* 2007;19:308–13.
13. Mereu L, Ruffo G, Landi S, Barbieri F, Zaccoletti R, Fiaccavento A, et al. Laparoscopic treatment of deep endometriosis with segmental colorectal resection: short term morbidity. *J Minim Invasive Gynecol* 2007;14:463–9.
14. Chapron C, Pietin-Vialle C, Borghese B, Davy C, Foulot H, Chopin N. Associated ovarian endometrioma is a marker for greater severity of deeply infiltrating endometriosis. *Fertil Steril* 2009;92:453–7. Epub 2008 Aug 9.
15. Hart RJ, Hickey M, Maouris P, Buckett W. Excisional surgery versus ablative surgery for ovarian endometriomata. *Cochrane Database Syst Rev* 2008 Apr 16;(2):CD004992.
16. Beretta P, Franchi M, Ghezzi F, Busacca M, Zupi E, Bolis P. Randomized clinical trial of two laparoscopic treatments of endometriomas: cystectomy versus drainage and coagulation. *Fertil Steril* 1998;70:1176–80.
17. Alborzi S, Momtahan M, Parsanezhad ME, Dehbashi S, Zolghadri J. A prospective, randomized study comparing laparoscopic ovarian cystectomy versus fenestration and coagulation in patients with endometriomas. *Fertil Steril* 2004;82:1633–7.
18. Matsuzaki S, Houle C, Darcha C, Pouly JL, Mage G, Canis M. Analysis of risk factors for the removal of normal ovarian tissue during laparoscopic cystectomy for ovarian endometriosis. *Hum Reprod* 2009;24:1402–6. Epub 2009 Feb 26.
19. Koga K, Takemura Y, Osuga Y, Yoshino O, Hirota Y, Hirata T, et al. Recurrence of ovarian endometrioma after laparoscopic excision. *Hum Reprod* 2006;21:2171–4. Epub 2006 Apr 27.
20. Seracchioli R, Mabrouk M, Manuzzi L, Vicenzi C, Frascà C, Elmakky A, et al. Post-operative use of oral contraceptive pills for prevention of anatomical relapse or symptom-recurrence after conservative surgery for endometriosis. *Hum Reprod* 2009;24:2729–35. Epub 2009 Jul 22.
21. Seracchioli R, Mabrouk M, Frascà C, Manuzzi L, Savelli L, Venturoli S. Long-term oral contraceptive pills and postoperative pain management after laparoscopic excision of ovarian endometrioma: a randomized controlled trial. *Fertil Steril* 2009 May 12. Epub ahead of print.
22. Daniels J, Gray R, Hills RK, Lathe P, Buckley L, Gupta J, et al.; LUND Trial Collaboration. Laparoscopic uterosacral nerve ablation for alleviating chronic pelvic pain: a randomized controlled trial. *JAMA* 2009;302:955–61.
23. Candiani GB, Fedele L, Vercellini P, Bianchi S, Di Nola G. Presacral neurectomy for the treatment of pelvic pain associated with endometriosis: a controlled study. *Am J Obstet Gynecol* 1992;167:100–3.
24. Zullo F, Palomba S, Zupi E, Russo T, Morelli M, Cappiello F, et al. Effectiveness of presacral neurectomy in women with severe dysmenorrhea caused by endometriosis who were treated with laparoscopic conservative surgery: a 1-year prospective randomized double-blind controlled trial. *Am J Obstet Gynecol* 2003;189:5–10.
25. Zullo F, Palomba S, Zupi E, Russo T, Morelli M, Sena T, et al. Long-term effectiveness of presacral neurectomy for the treatment of severe dysmenorrhea due to endometriosis. *J Am Assoc Gynecol Laparosc* 2004;11:23–8.
26. Frishman GN, Salak JR. Conservative surgical management of endometriosis in women with pelvic pain. *J Minim Invasive Gynecol* 2006;13:546–58.
27. Wie HJ, Lee JH, Kyung MS, Jung US, Choi JS. Is incidental appendectomy necessary in women with ovarian endometrioma? *Aust N Z J Obstet Gynaecol* 2008;48:107–111.

Surgical Management of Infertility Associated With Endometriosis

Treatment of infertility caused by endometriosis consists of either surgical removal of endometriotic tissue with adhesiolysis in order to restore normal anatomy or assisted reproductive technology. Surgery is preferably performed by laparoscopy because the rate of complications other than major ones is approximately 40% lower than that of laparotomy.¹ Laparoscopy is associated with shorter hospitalization and recovery time than laparotomy, but the effectiveness of the 2 surgical approaches seems to be identical, even though laparoscopy is less adhesiogenic.²

INDICATIONS FOR LAPAROSCOPY

No pain; normal results of pelvic examination

In infertile women with normal results of pelvic examination and regular ovulation, bilaterally patent fallopian tubes according to hysterosalpingography, and a normal spermogram of the male partner, the additional benefit of diagnostic laparoscopy with concomitant treatment of minimal endometriosis is still controversial. One prospective RCT could not find a difference in pregnancy rates between the treatment and no treatment groups.³ However, a larger Canadian study proved diagnostic laparoscopy with concomitant treatment of minimal and mild endometriosis to be effective and worthwhile.⁴ The efficiency of this procedure (that is, the number needed to treat), however, is quite deceiving: only 1 additional pregnancy will result among every 8 patients undergoing laparoscopic surgery. Because of limited access to public funding for assisted reproductive technology, many women and their physicians choose laparoscopy. Some national specialty societies, indeed, recommend laparoscopy in such cases.⁵

The decision to perform diagnostic laparoscopy in infertile women with no other apparent problem should be made on an individual basis, according to the woman's age and after discussion about the benefits and risks of surgery, as well as other options, such as ovulation induction and IVF.

Pain or abnormal results of pelvic examination

Laparoscopy is also indicated in the following instances.

1. When there is deep dyspareunia, severe dysmenorrhea, dyschezia, or chronic pelvic pain that is severe enough to cause distress: then the likelihood of finding endometriosis at laparoscopy is greatly increased.⁶ Surgery is indicated not only to improve fertility but also to ameliorate pain.
2. When tender nodules are palpated in the uterosacral ligaments: this finding should alert one to the possibility of deeply infiltrating endometriosis.⁷ Surgical excision of deep endometriotic lesions has been associated with improved fertility in 1 study.⁸
3. When there is a persistent adnexal mass: in approximately 48% of infertile patients undergoing diagnostic laparoscopy, there is evidence of endometriotic lesions of the ovary, from superficial implants to large cysts up to 12 cm in diameter.⁹ Ultrasonography, particularly transvaginal, has been shown to be both sensitive (84% to 90%) and specific (almost 100%) for the diagnosis of endometrioma.¹⁰ Endometriomas may be asymptomatic or can cause pain from distention or rupture. Surgical removal is often recommended for those with a diameter greater than 3 cm. Studies more than a decade ago demonstrated that medical management, independent of the prescribed product, led to a reduction in the size of the endometrioma but not to complete regression.^{11,12} In addition, surgical exploration is warranted if there is a concern about malignant disease.¹³

SURGICAL PRINCIPLES AND TECHNIQUES

Laparoscopy is the preferred surgical approach for treatment of infertility related to endometriosis. The goal of laparoscopic surgery is to remove endometriotic lesions as much as possible, restore normal anatomy with adhesiolysis, and optimize ovarian and tubal preservation and integrity with use of the principles of microsurgery (magnification, diligent hemostasis, reduced fulguration, avoidance of tissue drying, and limited use of sutures).¹⁴

Clinical Tips

- Adherence to principles of microsurgery such as diligent hemostasis, reduced fulguration, and limited use of sutures may improve fertility.
- Excision is preferred over fenestration, drainage, or ablation of the cyst lining for the treatment of an ovarian endometrioma.
- Use of adhesion-prevention adjuncts may help reduce adhesion formation but improvement in fertility is unknown.

Laparoscopic evaluation

This procedure is conducted to establish the severity of the disease by staging and looking at other areas, such as appendix, bowel, and diaphragm. In addition, any adnexal mass can be evaluated by peritoneal cytology and frozen section in case of doubt. The blue dye test can be performed to evaluate tubal patency.

Adhesiolysis

Adhesiolysis is performed to restore normal anatomy as much as possible. With the adhesions under tension, they are divided far from the most vital structure. The ovaries are freed from their adhesions to the pelvic sidewall before any ovarian cyst is removed; this process will often rupture the endometrioma and enable cystectomy.

Treatment of superficial endometriosis

With regard to improvement of fertility, there is no evidence that excision is better than ablation, and any modality used for ablation (electrosurgery or laser) has the same effectiveness.⁴

Treatment of endometriomas and deeply infiltrating endometriosis

See Chapter 4 for a description of the surgical approach.

Adhesion-prevention adjuncts

Even when surgery is performed by laparoscopy, adhesions can occur, and for many procedures the adhesion-related complications of open and laparoscopic gynaecologic surgery are similar.¹⁵ Pharmacologic agents such as antibiotics, corticosteroids, NSAIDs, and fibrinolytics have not been proven effective. Many types of physical separators are available in Canada. Other agents include gel barriers, such as 4% icodextrin solution (Adept). Although these agents are potentially useful, and there is some clinical evidence for

the reduction of adhesion formation, research into more effective preventive agents is required since improvement in fertility from the use of these agents is still unknown.¹⁴

Summary Statements

1. Laparoscopic treatment of minimal or mild endometriosis improves pregnancy rates regardless of the treatment modality. (I)
2. The effect on fertility of surgical treatment of deeply infiltrating endometriosis is controversial. (II)
3. Laparoscopic excision of ovarian endometriomas more than 3 cm in diameter may improve fertility. (II)

REFERENCES

1. Fuller J, Ashar BS, Carey-Corrado J. Trocar-associated injuries and fatalities: an analysis of 1399 reports to the FDA. *J Minim Invasive Gynecol* 2005;12:302–7.
2. Winkel CA. Evaluation and management of women with endometriosis. *Obstet Gynecol* 2003;102:397–408.
3. Parazzini F. Ablation of lesions or no treatment in minimal– mild endometriosis in infertile women: a randomized trial. Gruppo Italiano per lo Studio dell'Endometriosi. *Hum Reprod* 1999;14:1332–4.
4. Marcoux S, Maheux R, Bérubé S. Laparoscopic surgery in infertile women with minimal or mild endometriosis. Canadian Collaborative Group on Endometriosis. *N Engl J Med* 1997;337:217–22.
5. Royal College of Obstetricians and Gynaecologists. The investigation and management of endometriosis (green-top guideline; no. 24). London (England): RCOG;2006:3.
6. Scarselli G, Rizzello F, Cammilli F, Ginocchini L, Coccia ME. Diagnosis and treatment of endometriosis. A review. *Minerva Ginecol* 2005;57:55–78.
7. Cornillie FJ, Oosterlynck D, Lauweryns JM, Konicx PR. Deeply infiltrating pelvic endometriosis: histology and clinical significance. *Fertil Steril* 1990;53:978–83.
8. Capron C, Fritel X, Dubuisson JB. Fertility after laparoscopic management of deep endometriosis infiltrating the uterosacral ligaments. *Hum Reprod* 1999;14:329–32.
9. Rock JA, Breech LL. Surgery for anomalies of the Müllerian ducts. In: Rock JA, Jones HW, eds. *Te Linde's Operative gynecology*. 9th ed. Philadelphia: Lippincott Williams & Wilkins; 2003.
10. Somigliana E, Vercellini P, Viganó P, Ragni G, Crosignani PG. Should endometriomas be treated before IVF-ICSI cycles? *Hum Reprod* 2006;21:57–64.
11. Donnez J, Nisolle-Pochet M, Clerckx-Braun F, Sandow J, Casanas-Roux F. Administration of nasal buserelin as compared with subcutaneous buserelin implant for endometriosis. *Fertil Steril* 1989;52:27–30.
12. Rana N, Thomas S, Rotman C, Dmowski WP. Decrease in the size of ovarian endometriomas during ovarian suppression in stage IV endometriosis. Role of preoperative medical treatment. *J Reprod Med* 1996;41:384–92.
13. Brinton LA, Gridley G, Persson I, Baron J, Bergqvist A. Cancer risk after a hospital discharge diagnosis of endometriosis. *Am J Obstet Gynecol* 1997;176:572–9.
14. DeWilde RL, Trew RG. Postoperative abdominal adhesions and their prevention in gynaecological surgery. Expert consensus position. Part 2 – steps to reduce adhesions. *Gynecol Surg* 2007;4:243–53.
15. Lower AM, Hawthorn RJ, Ellis H, O'Brien F, Buchan S, Crowe AM. The impact of adhesions on hospital readmissions over ten years after 8849 open gynaecological operations: an assessment from the Surgical and Clinical Adhesions Research Study. *Br J Obstet Gynaecol* 2000;107:855–62.

Medical Treatment of Infertility Related to Endometriosis

The prevalence of endometriosis in infertile women ranges from 25% to 50% compared with 5% in fertile women.¹ A complete understanding of the mechanisms causing endometriosis-associated infertility remains elusive. Distortion of pelvic anatomy by adhesions, resulting in mechanical blockage of the fallopian tubes or impaired ovum release from the ovary may explain infertility in more advanced stages of endometriosis; however, in minimal or mild endometriosis the mechanism is not clear. A recent review points to the roles of inflammation, immune response, and angiogenesis in a complex pathologic process impairing fertility in early-stage endometriosis.²

There is an observed association between endometriosis and infertility, although a causal relationship has not been proven. Monthly fecundity is lower in women with endometriosis than in women without this condition, and there is a higher prevalence of endometriosis in infertile women than in fertile women undergoing tubal ligation.³ The most convincing evidence for an association between endometriosis and infertility comes from a prospective study of therapeutic donor insemination in which monthly fecundity was 0.12 in women without endometriosis and 0.036 in those with minimal endometriosis.⁴ It also appears that the lesions of endometriosis play little role in any potential cause of infertility: a prospective RCT of laparoscopic ablation of endometriotic lesions compared with expectant management showed a slightly increased fecundity rate in the 9 months after treatment,⁵ but the rate was still significantly lower than that observed in normal fertile women.⁶ To date, there is no convincing evidence for a plausible biologic mechanism of infertility in patients with mild to moderate endometriosis.

HORMONAL TREATMENT

Hughes et al.⁷ conducted a meta-analysis of all RCTs of ovulation suppression in women with endometriosis and the effect on fertility. The results suggested that suppressing ovarian function to improve fertility in minimal to mild

endometriosis is not effective and should not be offered for this indication alone. In addition, hormonal suppression before or after surgical treatment of endometriosis is contraindicated since there is no evidence of increased effectiveness over that of surgery alone, and the treatment prolongs or delays the opportunity for conception to occur.

ASSISTED REPRODUCTION

There is some evidence from RCTs that intrauterine insemination together with controlled ovarian stimulation may be effective in improving fertility in patients with endometriosis.⁸ The effect appears to be predominantly due to the ovarian stimulation, since intrauterine insemination alone may not be beneficial.

IN VITRO FERTILIZATION

Hormonal suppression for pre-treatment may be of use in patients with endometriosis and infertility who undergo IVF. It appears that IVF success rates are slightly lower in patients with endometriosis than in those with other diagnoses.⁹ However, several studies suggest that women with chronic or advanced endometriosis will benefit from long-term treatment with a GnRH agonist before an IVF cycle. Sallam et al.¹⁰ reviewed 3 RCTs of 165 women treated with IVF for infertility related to endometriosis. The clinical pregnancy rate per woman was significantly higher in those receiving GnRH agonist downregulation for 3 to 6 months before IVF than in the control group (OR 4.28, 95% CI 2.0 to 9.15). In addition, 1 of the studies that reported live birth rates also showed a significant benefit from pre-treatment with a GnRH agonist.

CONCLUSION

It appears that medical management of infertility in the form of hormonal suppression is not effective in improving fecundity rates in patients with endometriosis and should not be offered. On the other hand, the use of GnRH agonist suppression of ovarian function for 3 to 6 months before an

Clinical Tips

- Three months of suppression with a GnRH agonist and HT addback before IVF in women who have pelvic pain and infertility associated with endometriosis will greatly improve quality of life and reduce discomfort during ovarian stimulation and oocyte retrieval.
- Women with endometriosis-related infertility over the age of 35 years should be referred for IVF.

IVF cycle may improve the rates of clinical pregnancy and live birth in endometriosis patients.

Summary Statement

1. If a patient with known endometriosis is to undergo IVF, GnRH agonist suppression with HT addback for 3 to 6 months before IVF is associated with an improved pregnancy rate. (I)

Recommendation

1. Medical management of infertility related to endometriosis in the form of hormonal suppression is ineffective and should not be offered. (I-E)

REFERENCES

1. Littman E, Giudice L, Lathi R, Berker B, Milki A, Nezhat C. Role of laparoscopic treatment of endometriosis inpatients with failed in vitro fertilization cycles. *Fertil Steril* 2005;84:1574–8.
2. Bulun SE. Endometriosis. *N Engl J Med* 2009;360:268–79.
3. D'Hooghe T, Debrock S, Hill JA, Mauleman C. Endometriosis and subfertility: is the relationship resolved? *Semin Reprod Med* 2003;21:243–54.
4. Jansen RP. Minimal endometriosis and reduced fecundability: prospective evidence from an artificial insemination by donor program. *Fertil Steril* 1986;46(1):141–3.
5. Marcoux S, Maheux R, Bérubé S; Canadian Collaborative Group on Endometriosis. Laparoscopic surgery in infertile women with minimal or mild endometriosis. *N Engl J Med* 1997;337:217–22.
6. Schwartz D, Mayaux MJ. Female fecundity as a function of age: results of artificial insemination in 2193 nulliparous women with azoospermic husbands. *Federation CECOS. N Engl J Med* 1982;307:404–6.
7. Hughes E, Brown J, Collins JJ, Farquhar C, Fedorkow DM, Vandekerckhove P. Ovulation suppression for endometriosis. *Cochrane Database Syst Rev* 2007 Jul18;(3):CD000155.
8. Tummon IS, Asher LJ, Martin JS, Tulandi T. Randomized controlled trial of superovulation and insemination for infertility associated with minimal or mild endometriosis. *Fertil Steril* 1997;68:8–12.
9. Barnhart K, Dunsmoor-Su R, Coutifaris C. Effect of endometriosis on in vitro fertilization. *Fertil Steril* 2002;77:1148–55.
10. Sallam HN, Garcia-Velasco JA, Dias S, Arici A. Long-term pituitary down-regulation before in vitro fertilization (IVF) for women with endometriosis. *Cochrane Database Syst Rev* 2006 Jan 25;(1):CD004635.

Endometriosis in Adolescents

Endometriosis is recognized to be a cause of both pain and infertility in women of reproductive age. However, it is increasingly apparent that symptoms of endometriosis may begin in adolescence. The presentation of endometriosis in this age group may vary from that of adult women. It is important for health care providers assessing young women with pelvic pain and dysmenorrhea to consider endometriosis in their differential diagnosis to avoid delays in diagnosis and management.

The Endometriosis Association registry reports that 38% of women with endometriosis had symptoms starting before age 15 years and that when symptoms begin before age 15 an average of 4.2 physician consultations is required before a diagnosis is reached, more than in any other age group.¹ Early diagnosis and referral will help young women receive the necessary education about their symptoms and appropriate treatment.

PRESENTATION

Initial delay in the diagnosis of endometriosis in adolescents may in part be because the pain is attributed to primary dysmenorrhea and hence a “normal” part of growing up. When pelvic pain interferes with daily activities (such as school and work) it requires attention and management. Ten percent of dysmenorrhea in adolescents is secondary to other conditions.²

Secondary dysmenorrhea should be suspected in patients not responding to first-line agents (NSAIDs and CHCs) for the treatment of primary dysmenorrhea.³ Endometriosis is the most common cause of secondary dysmenorrhea in adolescents.² As primary dysmenorrhea occurs with the establishment of ovulatory cycles (in mid- and late adolescence), the onset of dysmenorrhea soon after the onset of menarche (within the first 6 months) should raise the consideration of a secondary cause and, in particular, asymmetrically obstructed outflow tracts with Müllerian anomalies. Coexistence of endometriosis and obstructed outflow tracts is presumed to be due in part to excess retrograde menstruation. Congenital anomalies of the reproductive tract have been found in up to 11% of adolescents with endometriosis,^{4,5} and endometriosis is reported to be present in up to 76% of patients with Müllerian anomalies and outflow tract obstruction.⁶ Initial surgery can be limited to relief of the

obstruction, since this may be followed by resolution of the endometriosis.^{7,8}

Adolescents with endometriosis have a variable pain history. Whereas 9.4% will complain of cyclic pain alone, more than 90% have an acyclic pain pattern with or without dysmenorrhea.³ As adolescents may not be sexually active when they present and are rarely seeking fertility assessment, dyspareunia and infertility are not part of the usual adolescent symptomatology.

PREVALENCE

It is hard to provide a general prevalence rate for adolescent endometriosis. Endometriosis has been diagnosed by laparoscopy among adolescent girls and young women (under 19 to 21 years) with dysmenorrhea and chronic pelvic pain not controlled by NSAIDs or CHCs at rates between 35.5% and 70% to 73%.^{3,9,10}

Endometriotic-like lesions (vascular proliferation, hemosiderin deposits, stroma but no endometrial glands) have been documented in premenarcheal girls with breast sexual maturity ratings of I to III and no Müllerian anomalies.¹¹ Treatment of the lesions reduced the pelvic pain. Hence, the onset of thelarche may be considered a developmental milestone at which endometriosis should be considered in the differential diagnosis of pelvic pain.

DIAGNOSIS

The approach to diagnosing endometriosis in adolescents should include detailed history-taking, an age-appropriate physical examination, and diagnostic imaging. As adolescents may have limited experience with seeking health care for gynaecologic issues, establishing rapport is important. A health risk screening tool such as the HEADSS assessment¹² may assist the health care provider. HEADSS is a framework for history-taking that begins with topics the adolescent may have more comfort discussing and concludes with more sensitive questions: **H**ome or housing, **E**ducation and employment, **A**ctivities, **D**rugs, **S**exual activity and sexuality, and **S**uicide and depression. Privacy and confidentiality should be explained to both the adolescent and her family early on in the health care visit.

Completing a pelvic examination of the young adolescent may be challenging; however, it is valuable to help rule out

pelvic masses and obstructive outflow tract anomalies. Flexibility should be applied when deciding on the extent of an examination. Whereas patients with a completely obstructed outflow tract (e.g., with an imperforate hymen or a transverse vaginal septum) may present with cyclic pain, they also will have primary amenorrhea and often a pelvic mass. Inspection of the external genitalia, with separation and traction of the labia, may demonstrate low outflow tract anomalies. Ruling out asymmetric outflow tract anomalies such as obstructing hemivaginal septum and non-communicating functional uterine horns, which may cause severe cyclic pain, is important. It may be possible to insert a cotton-tipped swab into the vagina to ensure that it is of normal length if a bimanual and speculum examination is not possible. A recto-abdominal examination allows palpation for pelvic masses. For older, sexually active adolescents, a physical examination is important to rule out other causes of pain, such as pelvic inflammatory disease, ovarian cysts, and complications of pregnancy.

The physical findings will often be normal in this age group even when endometriosis is present. Cul-de-sac nodularity, adnexal masses, and a fixed, retroverted uterus are uncommon in adolescents with endometriosis,^{11,13} as the disease is predominantly ASRM stage I or II.^{3,14} Deeply infiltrating endometriosis, although uncommon, may occur in adolescents. Rectovaginal, uterovesical, full-thickness bowel, and ureteric endometriosis have been diagnosed in this age group, although at a median age of 19 years.¹⁰

Pelvic imaging is an adjunct for diagnosis in the adolescent. If the young patient declines or is unable to have a physical examination, pelvic ultrasonography can assist with providing additional information to guide diagnosis and management. Pelvic imaging with ultrasonography and MRI is essential if a Müllerian anomaly is suspected.

MANAGEMENT

Empiric treatment with NSAIDs and CHCs is appropriate for most adolescents with dysmenorrhea.¹⁵ However, patients who do not respond to these medications require early referral for further investigations, which may include laparoscopy for diagnosis and treatment. Treatment algorithms for adolescents with endometriosis are extrapolated from adult research primarily and are based on expert opinion. There is very limited information on response to either medical or surgical therapy in this age group.

Although all medical and surgical options for endometriosis may be included in the care of adolescents, the health care provider needs to consider the patient's age and the side-effect profiles of the various agents; in particular, there is potential for bone loss with GnRH agonists and depot progestin.

A stepwise approach is usual for medical management, starting with CHC therapy in an extended or continuous fashion. Empiric GnRH agonist therapy with HT addback is reserved for adolescents over the age of 18 years owing to the concern of detrimental effects on BMD.^{16,17} With confirmation of an endometriosis diagnosis at surgery, continuous therapy with a CHC or a GnRH agonist with HT addback may be prescribed for adolescents as young as 16 years who have persistent problematic pelvic pain. A GnRH agonist is generally not recommended for patients under the age of 16 years.¹⁶ If GnRH agonist with HT addback therapy is prescribed, general advice about bone health maintenance, such as supplemental calcium and vitamin D intake, should be provided and consideration given to the monitoring of BMD. Anecdotal experience with an LNG-IUS has been reported.¹⁸

The timing of surgical management of endometriosis in adolescents is controversial. Laparoscopy, if performed, should be done by experienced surgeons who will recognize that younger patients have atypical endometriotic lesions, with more clear vesicles and red lesions and fewer classic "powder-burn" lesions,^{5,9,13} and should include resection or ablation of lesions for pain treatment.

Laparoscopy can confirm endometriosis before the introduction of GnRH agonist therapy when adolescents have pervasive pelvic pain despite initial medical therapy. The literature on outcomes of surgical resection of endometriotic lesions in adolescents is limited and involves small numbers of patients.⁵ In a study of 11 surgically treated women under age 21 years who had mild, moderate, or severe endometriosis and were given postoperative medical management (LNG-IUS, extended use of CHCs, or DMPA), 8 either became completely pain-free or had greatly reduced pain.¹⁰ Others have demonstrated an up to 84% reduction in symptoms.⁵

Like other women with chronic pelvic pain, adolescents may be helped by multimodal therapy and a biopsychosocial model of care. Behavioural modification

Clinical Tip

The approach to pelvic examination in adolescents should be flexible. Inspection, a recto-abdominal examination, and testing of the length of the vagina with a cotton-tipped swab can be used in not sexually active adolescents to investigate secondary dysmenorrhea.

techniques (such as biofeedback, relaxation, and hypnosis), cognitive therapy, and complementary therapies (such as acupuncture) may be used in a multidisciplinary approach.^{19,20}

Summary Statements

1. Endometriosis is the most common cause of secondary dysmenorrhea in adolescents. (II-2)
2. Adolescents with endometriosis are more likely than adult women to present with acyclic pain. (III)
3. The physical examination of adolescents with endometriosis will rarely reveal abnormalities, as most will have early-stage disease. (II-2)

Recommendations

1. Endometriosis in adolescents is often early stage and atypical. Laparoscopists should look intra-abdominally for clear vesicles and red lesions in adolescents. (II-2B)
2. All available therapies for endometriosis may be used in adolescents, but the age of the patient and the side-effect profiles of the medications should be considered. (III-A)

REFERENCES

1. Ballweg ML. Big picture of endometriosis helps provide guidance on approach to teens: comparative historical data show endo starting younger, is more severe. *J Pediatr Adolesc Gynecol* 2003;16(3 Suppl):S21–6.
2. Harel Z. A contemporary approach to dysmenorrhea in adolescents. *Pediatr Drugs* 2002;4:797–805.
3. Laufer MR, Goietein L, Bush M, Cramer DW, Emans SJ. Prevalence of endometriosis in adolescent girls with chronic pelvic pain not responding to conventional therapy. *J Pediatr Adolesc Gynecol* 1997;10:199–202.
4. Goldstein DP, De Cholnoky C, Emans SJ. Adolescent endometriosis. *J Adolesc Health Care* 1980;1:37–41.
5. Davis GD, Thillet E, Lindemann J. Clinical characteristics of adolescent endometriosis. *J Adolesc Health* 1993;14:362–8.
6. Olive D, Henderson D. Endometriosis and Müllerian anomalies. *Obstet Gynecol* 1987;69:412–5.
7. Sanfilippo J, Wakim N, Schikler K, Yussman M. Endometriosis in association with uterine anomaly. *Am J Obstet Gynecol* 1986;154:39–43.
8. Candiani GB, Fedele L, Candiani M. Double uterus, blind hemivagina, and ipsilateral renal agenesis: 36 cases and long-term follow-up. *Obstet Gynecol* 1997;90:26–32.
9. Reese KA, Reddy S, Rock JA. Endometriosis in an adolescent population: the Emory experience. *J Pediatr Adolesc Gynecol* 1996;9:125–8.
10. Stavroulis AI, Saridogan E, Creighton SM, Cutner AS. Laparoscopic treatment of endometriosis in teenagers. *Eur J Obstet Gynecol Reprod Biol* 2006;248–50.
11. Marsh EE, Laufer MR. Endometriosis in premenarcheal girls who do not have an associated obstructed anomaly. *Fertil Steril* 2005;83:758–60.
12. Gover S. Pelvic pain in the female adolescent. *Aust Fam Physician* 2006;35:850–3.
13. Vercellini P, Fedele L, Arcaini L, Bianchi S, Rognoni M, Candiani G. Laparoscopy in the diagnosis of chronic pelvic pain in adolescent women. *J Reprod Med* 1989;34:827–30.
14. Emmert C, Romann D, Riedel HH. Endometriosis diagnosed by laparoscopy in adolescent girls. *Arch Gynecol Obstet* 1998;261:89–93.
15. Davis AR, Westhoff C, O'Connell K, Gallagher N. Oral contraceptives for dysmenorrhea in adolescent girls. *Obstet Gynecol* 2005;106:97–104.
16. Templeman C. Adolescent endometriosis. *Obstet Gynecol Clin North Am* 2009;36:177–86.
17. DiVasta AD, Laufer MR, Gordon C. Bone density in adolescent treated with a GnRH agonist and add-back therapy for endometriosis. *J Pediatr Adolesc Gynecol* 2007;20:293–7.
18. Al-Jefout M, Palmer J, Fraser IS. Simultaneous use of a levonorgestrel intrauterine system and an etonogestrel subdermal implant for debilitating adolescent endometriosis. *Aust N Z J Obstet Gynaecol* 2007;47:247–9.
19. Greco D. Management of adolescent chronic pelvic pain from endometriosis: a pain center perspective. *J Pediatr Adolesc Gynecol* 2003;16(3 Suppl):S17–9.
20. Wayne PM, Kerr CE, Schnyer RN, Legedza ATR, Savetsky-German J, Shields MH, et al. Japanese-style acupuncture for endometriosis-related pelvic pain in adolescents and young women: results of a randomized sham-controlled trial. *J Pediatr Adolesc Gynecol* 2008;21:247–5.

Endometriosis and Cancer

Although endometriosis is a benign disease, it shares many characteristics with malignancy, such as invasive and unrestrained growth and a tendency to metastasize and recur. Epidemiologic and laboratory evidence links endometriosis to epithelial ovarian carcinoma.

In 1925, Sampson¹ was the first to describe criteria for malignancy originating from endometriosis:

1. the presence of both endometriosis and malignancy within the same ovary must be demonstrated,
2. the carcinoma must arise from the endometriosis and not invade it from another source, and
3. the specimen must contain histological characteristics of endometriosis including stroma and glands.

The demonstration of morphological continuation between benign and malignant epithelium within the endometriosis was added as a fourth criterion by Scott in 1953.² Since then, a large amount of evidence supporting a relationship between endometriosis and cancer has accumulated.

EPIDEMIOLOGY

Multiple large epidemiologic studies have been published to support a relationship between endometriosis and epithelial ovarian carcinoma, in particular the clear cell and endometrioid subtypes.³ In their retrospective cohort study, Brinton et al.⁴ reviewed the cases of more than 20 000 women with a diagnosis of endometriosis. They identified an increased overall cancer risk, and a more greatly increased ovarian cancer risk, with a standardized incidence ratio (SIR: the ratio of the observed numbers of cancers to those expected) of 1.2 (95% CI 1.1 to 1.3) and 1.9 (95% CI 1.3 to 2.8), respectively. Several other published reports support this association,^{5–8} including the study by Kobayashi et al.⁹ of 6398 women with endometriomas, which was documented surgically in one third of the women, and by ultrasound or physical examination in the remainder. After 17 years of follow-up, 46 ovarian cancers were identified (SIR 8.95; 95% CI 4.12 to 15.3).⁹ Analysis of pooled interview data from 8 case–control studies showed that women with infertility, especially those with endometriosis, were more likely to develop ovarian cancer (OR 1.73; 95% CI 1.10 to 2.71).¹⁰

Despite these findings, not all studies support an increased ovarian cancer risk in patients with

endometriosis. Olsen et al.¹¹ identified a cohort of 1392 post-menopausal women who self-reported a diagnosis of endometriosis among more than 37 000 postmenopausal women and followed them for an average of 13 years. No significant increased overall risk of cancer, including ovarian cancer, was identified. However, the endometriosis was self-reported, not medically confirmed, and only 3 ovarian cancers were diagnosed, which raises questions of bias and underpowering.

Prevalence ratios have also been investigated. Van Gorp et al.¹² reviewed 29 studies (n = 857) and reported that the prevalence of endometriosis in women with epithelial ovarian cancer was as follows: 1.4% for mucinous, 4.5% for serous, 19.0% for endometrioid, and 35.9% for clear cell carcinoma. In another study of 22 patients with endometrioid ovarian carcinoma, Valenzuela et al.¹³ confirmed malignant transformation of endometriosis in 3 patients, resulting in a prevalence of 14%.

Van Gorp et al.¹² also calculated the prevalence of ovarian cancer among women with endometriosis, based on a review of 8 studies (n = 3401). Using the criteria of Sampson¹ and Scott,² they estimated the prevalence of malignant transformation was 0.9% of all endometriosis lesions. When the definition of endometriosis-associated ovarian carcinoma was broadened to endometriosis and ovarian cancer present in the same ovary, the prevalence of ovarian cancer among women with endometriosis increased to 2.5%. When the definition of endometriosis-associated ovarian carcinoma was further expanded to include ovarian cancer that occurs in women with any form of pelvic endometriosis, then the prevalence of ovarian cancer in endometriosis increases to 4.5%.

PATHOPHYSIOLOGY

Epidemiologic evidence linking endometriosis and ovarian carcinoma may appear strong; however, the exact mechanism of malignant transformation remains unclear. In their review of the association between endometriosis and ovarian cancer, Somigliana et al.¹⁴ put forward two mechanisms to explain the association: (1) endometriosis cells may undergo transformation to malignancy, and (2) the coexistence of endometriosis and ovarian cancer may be due to shared risk factors and antecedent mechanisms. The first scenario suggests endometriosis may be a precursor lesion to ovarian

cancer. This theory is supported by histologic evidence of malignant transformation of endometriosis to clear cell or endometrioid carcinoma.¹⁵ Pathological and immunohistochemical studies of proliferation of endometriosis cells by Ogawa et al.¹⁶ showed that atypical endometriosis may be a precursor lesion to ovarian clear cell and endometrioid carcinoma. Studies of molecular genetic alterations also provide evidence that endometriosis may be a precursor lesion to carcinoma; however, further research is needed to define this mechanism.^{17,18} In the second scenario, endometriosis and ovarian cancer are two separate biological entities coupled by an indirect link, because similar factors predispose to both diseases. Several common risk factors have been identified for these conditions, in particular nulliparity, early menarche, and late menopause.³ The coexistence of the two conditions may also be a consequence of other shared mechanisms such as genetic predisposition, immune dysregulation, and environmental factors.¹⁴

Although a relationship appears to exist between endometriosis and ovarian cancer, an association between two conditions does not prove causality. Vigano et al.¹⁹ concluded that a causal relationship of low magnitude between endometriosis and specific histotypes of ovarian cancer should be recognized, but this relationship may also be explained by the fact that ectopic endometrium undergoes malignant transformation just as normal endometrium does.

MANAGEMENT

All adnexal masses found on examination and/or imaging preoperatively should be scrutinized and investigated for the possibility of underlying malignancy. Suspected ovarian endometriomas should be treated according to guidelines for the management of ovarian masses, including assessment with ultrasound and possibly serum CA 125 levels, although it is important to keep in mind that endometriosis may cause an elevated CA 125 level.^{20,21} In patients with a mass that appears to be an ovarian endometrioma, without other indicators of malignancy, follow-up surveillance should be considered if surgery is not indicated. Also, ovarian endometriomas that are surgically managed should be biopsied to exclude a concomitant malignancy.

The management of peritoneal endometriosis has been described in this guideline for patients with pain and infertility. Although the risk of concomitant malignancy is low, it may be reasonable to consider biopsy at the time of surgical management to help confirm a diagnosis and exclude an atypical or malignant process.

Summary Statements

1. The prevalence of ovarian cancer in patients with endometriosis is under 1%. (II-2)
2. Excision or sampling of suspected endometriosis lesions and endometriomas helps confirm the diagnosis and exclude underlying malignancy. (II-2)

Recommendations

1. Biopsy of endometriosis lesions should be considered to confirm the diagnosis and to rule out underlying malignancy. (II-2A)
2. Suspected ovarian endometriomas should be treated according to the SOGC guideline "Initial Evaluation and Referral Guidelines for Management of Pelvic/Ovarian Masses." (III-A)

REFERENCES

1. Sampson JA. Endometrial carcinoma of the ovary arising in endometrial tissue in that organ. *Arch Surg* 1925;10:1–72.
2. Scott RB. Malignant changes in endometriosis. *Obstet Gynecol* 1953;2:283–9.
3. Nezhat F, Datta MS, Hanson V, Pejovic T, Nezhat C, Nezhat C. The relationship of endometriosis and ovarian malignancy: a review. *Fertil Steril* 2008;90:1559–70.
4. Brinton LA, Gridley G, Persson I, Baron J, Bergqvist A. Cancer risk after a hospital discharge diagnosis of endometriosis. *Am J Obstet Gynecol* 1997;176:572–9.
5. Brinton LA, Sakoda LC, Sherman ME, Frederiksen K, Kjaer SK, Graubard BI, et al. Relationship of benign gynecologic diseases to subsequent risk of ovarian and uterine tumors. *Cancer Epidemiol Biomarkers Prev* 2005;14:2929–35.
6. Melin A, Sparen P, Persson I, Bergqvist A. Endometriosis and the risk of cancer with special emphasis on ovarian cancer. *Hum Reprod* 2006;21:1237–42.
7. Oral E, Ilvan S, Tustas E, Korbeyli B, Bese T, Demirkiran F, et al. Prevalence of endometriosis in malignant epithelial ovary tumours. *Eur J Obstet Gynecol Reprod Biol* 2003;109:97–101.
8. Borgfeldt C, Andolf E. Cancer risk after hospital discharge diagnosis of benign ovarian cysts and endometriosis. *Acta Obstet Gynecol Scand* 2004;83:395–400.
9. Kobayashi H, Sumimoto K, Moniwa N, Imai M, Takakura K, Kuromaki T, et al. Risk of developing ovarian cancer among women with ovarian endometrioma: a cohort study in Shizuoka, Japan. *Int J Gynecol Cancer* 2007;17:37–43.
10. Ness RB, Cramer DW, Goodman MT, Kjaer SK, Mallin K, Mosgaard BJ, et al. Infertility, fertility drugs, and ovarian cancer: a pooled analysis of case-control studies. *Am J Epidemiol* 2002;155:217–24.
11. Olson JE, Cerhan JR, Janney CA, Anderson KE, Vachon CM, Sellers TA. Postmenopausal cancer risk after self-reported endometriosis diagnosis in the Iowa women's health study. *Cancer* 2002;94:1612–8.
12. Van Gorp T, Amant F, Neven P, Vergote I, Moerman P. Endometriosis and the development of malignant tumours of the pelvis. A review of literature. *Best Pract Res Clin Obstet Gynaecol* 2004;18:349–71.
13. Valenzuela P, Ramos P, Redondo S, Cabrera Y, Alvarez I, Ruiz A. Endometrioid adenocarcinoma of the ovary and endometriosis. *Eur J Obstet Gynecol Reprod Biol* 2007; 134:83–6.
14. Somigliana E, Vigano P, Parazzini F, Stoppelli S, Giambattista E, Vercellini P. Association between endometriosis and cancer: a comprehensive review

- and a critical analysis of clinical and epidemiological evidence. *Gynecol Oncol* 2006;101:331–41.
15. Feeley KM, Wells M. Precursor lesions of ovarian epithelial malignancy. *Histopathology* 2001;38:87–95.
16. Ogawa S, Kaku T, Amada S, Kobayashi H, Hirakawa T, Ariyoshi K, et al. Ovarian endometriosis associated with ovarian carcinoma: a clinicopathological and immunohistochemical study. *Gynecol Oncol* 2000;77:298–304.
17. Prowse AH, Manek S, Varma R, Liu J, Godwin AK, Maher ER, et al. Molecular genetic evidence that endometriosis is a precursor of ovarian cancer. *Int J Cancer* 2006; 119:556–62.
18. Otsuka J, Okuda T, Sekizawa A, Amemiya S, Saito H, Okai T, et al. K-ras mutation may promote carcinogenesis of endometriosis leading to ovarian clear cell carcinoma. *Med Electron Microsc* 2004;37:188–92.
19. Vigano P, Somigliana E, Parazzini F, Vercellini P. Bias versus causality: interpreting recent evidence of association between endometriosis and ovarian cancer. *Fertil Steril* 2007;88:588–93.
20. Varma R, Rollason T, Gupta JK, Maher ER. Endometriosis and the neoplastic process. *Reproduction* 2004;127:293–304.
21. Le T, Giede C; SOGC/GOC/SCC Policy and Practice Guidelines Committee. Initial evaluation and referral guidelines for management of pelvic/ovarian masses. SOGC Joint Clinical Practice Guideline, No. 230, July 2009. *J Obstet Gynaecol Can* 2009;31:668–73.

National Office / Bureau national
Executive Vice-President /
Vice-président administratif
André B. Lalonde, MD, FRCSC – Ottawa

Associate Executive Vice-President /
Vice-présidente administrative
associée

Vyta Senikas, MD, FRCSC – Ottawa

The Society of Obstetricians and
Gynaecologists of Canada /
La Société des obstétriciens et
gynécologues du Canada
780 Echo Drive
Ottawa, Ontario K1S 5R7
tel: (613) 730-4192 or 1-800-561-2416
fax: (613) 730-4314
www.sogc.org

Published for the Society of Obstetricians
and Gynaecologists of Canada by the
Canadian Psychiatric Association /
Publié pour la Société des obstétriciens et
gynécologues du Canada par l'Association
des psychiatres du Canada
141 Laurier Avenue West, Suite 701,
Ottawa ON K1P 5J3

Director, Scientific Publications /
Directrice, Publications scientifiques
Virginia St-Denis

Editorial Coordinator and
Proofreader / Coordonnatrice à la
rédaction et correctrice d'épreuves
Dianne Vroom

Desktop Publisher / Micro-éditrice
Helen Cory

Periodicals Production Manager /
Gestionnaire, production des
periodiques
Smita Hamzeh

Online publishing /
Publication en ligne
Linda Kollesh

Marketing and advertising sales /
Marketing et publicité
Classified advertising /
Annonces classées
Reprints / Tirés à part

Keith Health Care
Marg Churchill
tel: (905) 278-6700 or 800 661-5004
fax: (905) 278-4850
mchurchill@keithhealthcare.com

JOGC is indexed by the National Library of
Medicine in Index Medicus and its online
counterpart MEDLINE and included in
NLM's PubMed system.

Le JOGC est répertorié par la *National
Library of Medicine* dans *Index Medicus* et
son équivalent en ligne, MEDLINE.
Il est également inclus dans le système
PubMed de la NLM.

All prescription drug advertisements have
been cleared by the Pharmaceutical
Advertising Advisory Board.



Toutes les annonces de médicaments
prescrits ont été approuvées par le Conseil
consultatif de publicité pharmaceutique

